

# BEYOND THE CLINICAL TRIALS

**An educational series on the implications  
of managing the ocular manifestations  
of diabetes in the real world.**

Imaging is critically important for diagnosing diabetic retinopathy and diabetic macular edema and it is equally important for following patients over time. With the expanding array of options available to retina specialists for capturing images of the retina, it is perhaps difficult to determine when and where each piece of technology fits in the care of these patients.

In part 3 of this ongoing series, Victor H. Gonzalez, MD, of Valley Research Institute in McAllen, Texas, explores the technology necessary to establish a baseline for each patient, how the clinical examination guides the use of imaging, and how to use optical coherence tomography and fluorescein angiography to follow patients over time. An overlooked aspect in the use of imaging, according to Dr. Gonzalez, is the changing reimbursement landscape for retina specialists and how it may change how patients are managed in the very near future.

Supported by advertising from Allergan Inc., and Heidelberg Engineering



# Non-Contact, Ultra-widefield Angiography

**SPECTRALIS®**

The future of diagnostic imaging

Obtain high contrast, undistorted images of the far periphery with the simple exchange of a lens.

All SPECTRALIS and HRA2 angiography systems can be upgraded with the new **Non-Contact Ultra-Widefield Angiography Module**, a cost-effective alternative to stand alone widefield imaging devices.

See more at [www.HeidelbergEngineering.com/us/ultra-widefield-imaging](http://www.HeidelbergEngineering.com/us/ultra-widefield-imaging)

[www.HeidelbergEngineering.com/us](http://www.HeidelbergEngineering.com/us)

SPECTRALIS is a registered trademark of Heidelberg Engineering, Inc.  
© 2015 Heidelberg Engineering, Inc. All rights reserved. 2719-002

**HEIDELBERG  
ENGINEERING**

# The Role of Imaging in Patients with DME

AN INTERVIEW WITH VICTOR H. GONZALEZ, MD

## What imaging modalities do you use during the initial evaluation of patients with diabetes?

**Victor Gonzalez, MD:** If I examine an eye and I see very little retinopathy on my slit lamp examination, I do not perform imaging studies. If, on the other hand, I see any type of retinopathy with macular thickening, I consider using optical coherence tomography (OCT) to assess the severity of the central macular thickening. If I do not see macular thickening during the clinical workup but I do note retinopathy in a patient with long standing, poorly controlled diabetes, I like to order a fluorescein angiogram (FA) to assess the status of the vasculature of not only the macula, but also the periphery (Figure 1).

Quite often in this group of patients the clinical examination does not show the severity of capillary loss detected by the angiogram, both in the posterior pole and the periphery. The FA allows me to detect treatable disease in the periphery, ie proliferative diabetic retinopathy, and gives me direction as to when to schedule my next follow-up, ie more often the more severe the capillary loss.

My approach can be summarized as follows: If there is no retinopathy, I do a fundus examination. If there is obvious thickening of the central macula or the macula in general, I will perform an OCT. If there is not any thickening that I can see on an examination, and there is moderate to severe diabetic retinopathy, then I will do an FA to assess the status of the vasculature in the posterior pole and the periphery.

## It sounds like you start with a clinical examination and history and let that inform what imaging you use.

**Dr. Gonzalez:** That is exactly right. My clinical examination and the history are the most important parts of my assessment of a patient with diabetes. Imaging is helpful to determine whether or not there is clinically significant macular edema, which I confirm based on my examination. The FA helps me stage the disease in patients who have more advanced retinopathy. I want to know how severe the vascular pathology is in the periphery, and that helps me determine how often I need to see the patient.

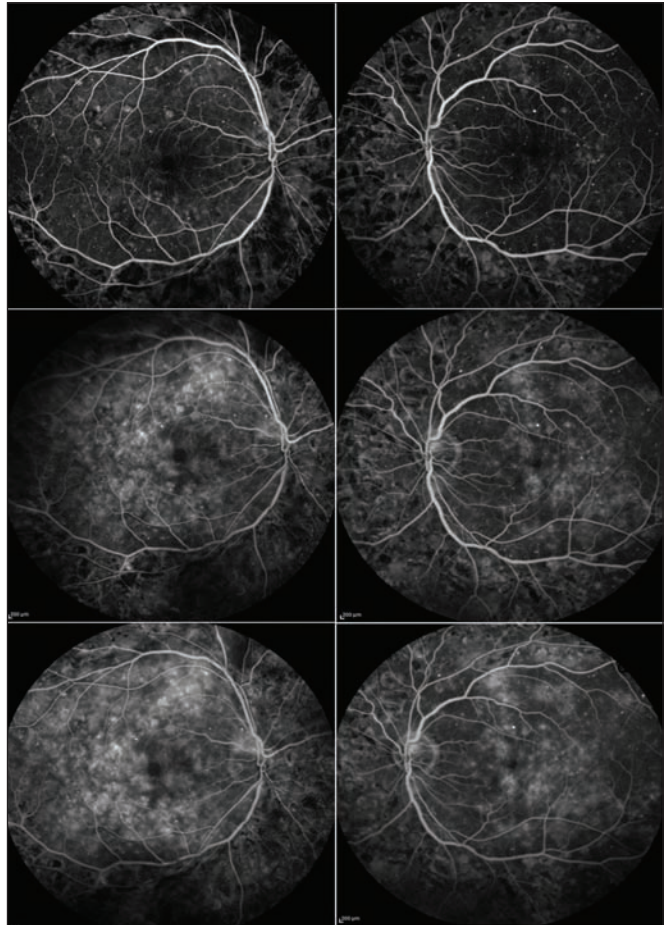


Figure 1. Baseline FA of a 49-year-old patient with a more than 35-year history of diabetes. The patient had severe macular edema on presentation, as confirmed by the early, mid, and late stage (from top to bottom) images from the right (left column) and left eye (right column).

## Do you make any distinction between patients with type 1 versus type 2 disease? Does that change your thinking in approaching imaging?

**Dr. Gonzalez:** Patients with type 1 diabetes present with an acute event when they become diabetic, so you know exactly how long they have had diabetes. Patients with type 2 diabetes can have a long history of disease before being diagnosed. If you look at the literature, the longer a patient has had diabetes, the higher the risk of developing retinopa-

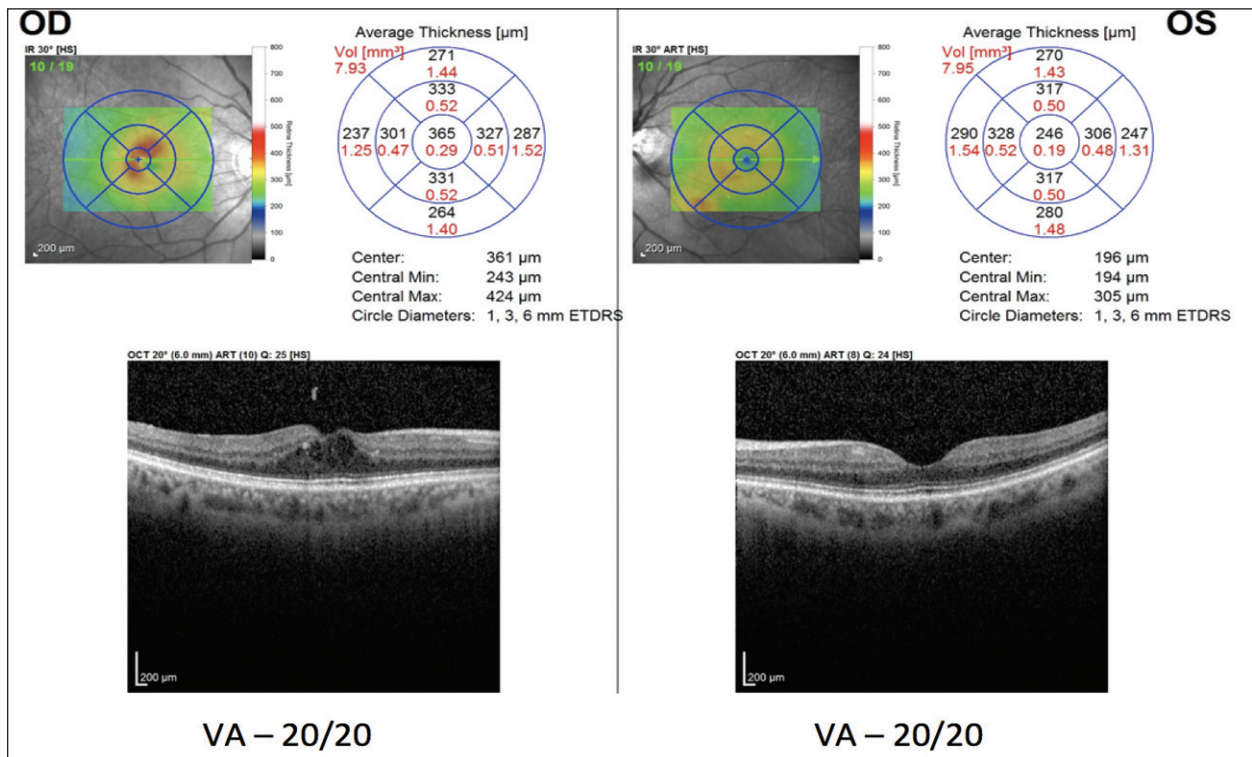


Figure 2. In the OCT of this patient, the left eye is normal, whereas the right eye demonstrates the classic findings associated with DME: intraretinal cysts and retinal thickening associated with changes one would expect from leaking microaneurysms.

thy. With patients with type 1 disease I know exactly how long they have had the disease. They rarely develop retinopathy before having the disease for 5 years. I usually do not order imaging early in the disease in these patients unless I detect significant retinopathy on my clinical examination. In a patient with type 2, I am not certain of the time they have had the disease. I will tend to order imaging earlier after diagnosis in these patients if I see significant retinopathy on clinical examination. Typically, I would order an FA to assess the posterior pole and the periphery. Again, this allows me to find treatable disease in the periphery earlier and gives me some guidance as to how often I need to follow the patient.

### In your opinion, is it necessary to perform a baseline FA?

**Dr. Gonzalez:** The vascular changes in eyes with diabetic retinopathy (DR) begin in the periphery, so if the examination is focused on the macular region there is a chance of missing retinopathy developing in the periphery. For this reason, I look at the status of the vasculature in both the macula and the periphery in patients that have long standing diabetes and have significant retinopathy. If I detect significant retinopathy on my clinical examination, then I order a baseline FA. I do not as a routine order an FA in patients presenting with no diabetic retinopathy.

### Does that also mean that your subsequent clinical examinations are going to determine how frequently you perform FA, and whether you need to use FA during subsequent visits?

**Dr. Gonzalez:** Absolutely. If on my follow-up examination the patient has no worsening of retinopathy or some loss of visual function, I do not order a FA.

### Are there any technologies currently available that can substitute for FA in terms of understanding the extent of vascular involvement?

**Dr. Gonzalez:** The clinical examination gives me an idea about which patients will need imaging. There are not yet any technologies currently available that can substitute for an FA. The angiogram is still the gold standard for determining and evaluating the retinal vasculature at present. There are some promising potential technologies such as OCT angiography, but it is still too early to know if that is going to replace FA or even to know how clinically useful it will be. The images look interesting, but there have not been any large-scale studies that demonstrate the clinical usefulness of these instruments.

There may be other studies and imaging modalities that retina specialists can use, and they may well have importance for assessing the health of an eye with diabetic complications. However, in an era of cost-conscious health care

The increase in mean IOP was seen with each treatment cycle, and the mean IOP generally returned to baseline between treatment cycles (at the end of the 6 month period).

### USE IN SPECIFIC POPULATIONS

#### Pregnancy Category C

##### Risk Summary

There are no adequate and well-controlled studies with OZURDEX® in pregnant women. Animal reproduction studies using topical ocular administration of dexamethasone were conducted in mice and rabbits. Cleft palate and embryofetal death in mice and malformations of the intestines and kidneys in rabbits were observed. OZURDEX® should be used during pregnancy only if the potential benefit justifies the potential risk to the fetus.

##### Animal Data

Topical ocular administration of 0.15% dexamethasone (0.375 mg/kg/day) on gestational days 10 to 13 produced embryofetal lethality and a high incidence of cleft palate in mice. A dose of 0.375 mg/kg/day in the mouse is approximately 3 times an OZURDEX® injection in humans (0.7 mg dexamethasone) on a mg/m2 basis. In rabbits, topical ocular administration of 0.1% dexamethasone throughout organogenesis (0.13 mg/kg/day, on gestational day 6 followed by 0.20 mg/kg/day on gestational days 7-18) produced intestinal anomalies, intestinal aplasia, gastroschisis and hypoplastic kidneys. A dose of 0.13 mg/kg/day in the rabbit is approximately 4 times an OZURDEX® injection in humans (0.7 mg dexamethasone) on a mg/m2 basis.

**Nursing Mothers:** Systemically administered corticosteroids are present in human milk and can suppress growth and interfere with endogenous corticosteroid production. The systemic concentration of dexamethasone following intravitreal treatment with OZURDEX® is low. It is not known whether intravitreal treatment with OZURDEX® could result in sufficient systemic absorption to produce detectable quantities in human milk. Exercise caution when OZURDEX® is administered to a nursing woman.

**Pediatric Use:** Safety and effectiveness of OZURDEX® in pediatric patients have not been established.

**Geriatric Use:** No overall differences in safety or effectiveness have been observed between elderly and younger patients.

### NONCLINICAL TOXICOLOGY

#### Carcinogenesis, Mutagenesis, Impairment of Fertility

No adequate studies in animals have been conducted to determine whether OZURDEX® (dexamethasone intravitreal implant) has the potential for carcinogenesis. Although no adequate studies have been conducted to determine the mutagenic potential of OZURDEX®, dexamethasone has been shown to have no mutagenic effects in bacterial and mammalian cells *in vitro* or in the *in vivo* mouse micronucleus test. Adequate fertility studies have not been conducted in animals.

### PATIENT COUNSELING INFORMATION

#### Steroid-related Effects

Advise patients that a cataract may occur after repeated treatment with OZURDEX®. If this occurs, advise patients that their vision will decrease, and they will need an operation to remove the cataract and restore their vision.

Advise patients that they may develop increased intraocular pressure with OZURDEX® treatment, and the increased IOP will need to be managed with eye drops, and, rarely, with surgery.

#### Intravitreal Injection-related Effects

Advise patients that in the days following intravitreal injection of OZURDEX® patients are at risk for potential complications including in particular, but not limited to, the development of endophthalmitis or elevated intraocular pressure.

#### When to Seek Physician Advice

Advise patients that if the eye becomes red, sensitive to light, painful, or develops a change in vision, they should seek immediate care from an ophthalmologist.

#### Driving and Using Machines

Inform patients that they may experience temporary visual blurring after receiving an intravitreal injection. Advise patients not to drive or use machines until this has been resolved.

and declining reimbursement, I am not sure we will be able to perform all of the imaging we want. I believe we are moving toward a new way of thinking where the least expensive study that gives you the best results will be the way to go. I think the days of ordering multiple studies to help confirm the results of the first are over. Unless the second study adds a clear value to the treatment of the patient there will be a restriction on their use. As the payment models change, we are going to move more and more toward a global cap type of payment. That means, basically, that we will get a fixed budget to take care of a patient with a specific diagnosis, which is then going to force us to look for studies and interventions that return the best quality outcome at the lowest cost. That is going to be a change how we care for patients our patients in the future.

### Has widefield imaging been validated enough to drive clinical decision-making in patients with DR? Could it replace the clinical examination?

Dr. Gonzalez : I do not think widefield imaging will ever

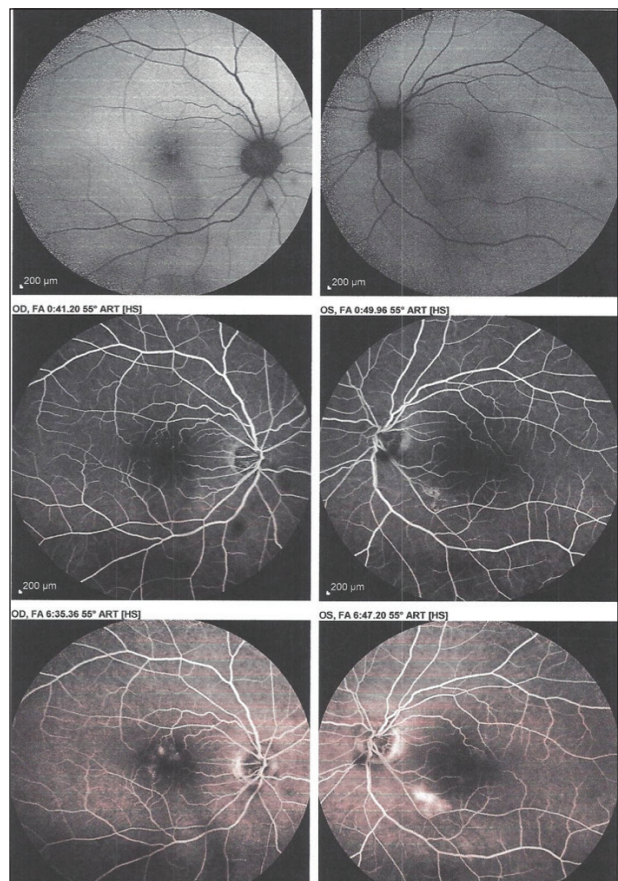


Figure 3. A baseline FA in a 61-year-old patient exhibits localized leakage. Also notable is that there are microaneurysms leaking into the central macula in the left eye and a lesion further away from the center, which may explain why this patient did not report visual symptoms at the time of examination.

# Atypical Cases of Diabetic Macular Edema

BY VICTOR H. GONZALEZ, MD

It goes without saying that no 2 cases of diabetic macular edema will present in the same way. There can be significant variability in baseline presentation influenced by a number of factors (ie, type 1 vs type 2 disease, duration of disease, blood glucose control, concomitant disease, and etc.); equally, patients' responses to therapies are highly individualized. Therefore, we should seek to individualize therapy as much as possible, and that means considering all the options available for treatment.

For example, I had a 49-year-old patient present to my clinic with a history of blurred vision which was getting progressively worse in both eyes (Video 1; [eyetube.net/?v=ifire](http://eyetube.net/?v=ifire)), a more than 35-year history of diabetes, and a 12-year history of hypertension. The intraocular pressure was normal, but early cataracts were forming in both eyes. This patient had significant edema apparent on imaging and clinical examination, although no ischemia was noted. The unusual element to this case is that there was non-center-involving edema in the right eye, and there really is no data to suggest a benefit with anti-VEGF therapy in such patients.

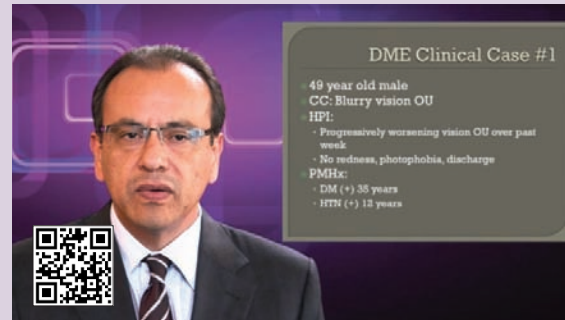
I opted to try anti-VEGF therapy, and the patient demonstrated improvement in both functional (ie, visual acuity) and anatomical outcomes. In keeping with my own protocol, I followed this patient over time and extended the interval between doses. I also like to have patients use the Amsler grid to monitor for visual acuity changes between visits.

Another case involved a 61-year-old woman with an A1C level of 6.7 and a more than 10-year history of hypertension and hypercholesterolemia (Video 2; [eyetube.net/?v=opuru](http://eyetube.net/?v=opuru)). Although the patient presented with 20/20 visual acuity in both eyes, there was leakage on the fluorescein angiogram. However, this patient does not really fit in the current treatment criteria because visual acuity is not worse than 20/40.

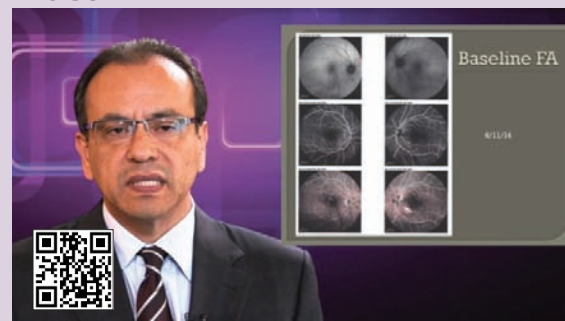There were some concerning elements to this patient's presentation that had me considering treatment (laser treatment, although that may yield a toxic effect on final visual acuity); yet, I opted for observation with a strong recommendation to the patient to gain metabolic control—something we should be doing for all patients with diabetes. The patient's edema did resolve a bit over time, which added to my comfort level with observation alone. I suspect that improved metabolic control was significant in this patient: 6 months later, she had an A1C level of 5.9 and the macular edema had resolved.

Another case involved a 54-year-old woman with complaints of blurry vision in both eyes (Video 3; [eyetube.net/?v=ibeko](http://eyetube.net/?v=ibeko)). She had a 12-year history of diabetes and hypertension and hypercholesterolemia. She also had

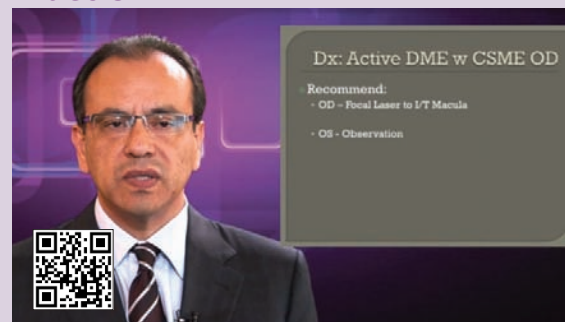## Video 1



## Video 2



## Video 3



localized leakage and a prior history of photocoagulation to treat her edema. Although typical ETDRS-type laser treatment is associated with a toxic response by the macula, localized focal treatment with low-energy parameters have resulted in good outcomes and decreased toxic effects to the tissues, and so this is what I opted for as initial therapy. I later added anti-VEGF therapy. To me, this case demonstrates that, in certain patients, despite the efficacy of pharmacologic approaches, that focal laser is still an appropriate option.

replace the clinical examination, but I think widefield OCT and widefield angiography are helpful complementary tools. They can help us confirm what we think we see on our examinations. There are some pathologies that can be picked up only with widefield angiography. I use the Heidelberg wide-viewing system on the Spectralis for angiograms and it is helpful for certain pathologies, ie evaluating capillary nonperfusion/presence of proliferative DR, but I use it more as a confirmatory examination rather than a screening tool. There is a potential to use imaging for screening, but studies are needed to prove that it is cost effective and safe.

### What are the hallmark findings on OCT and/or FA that you look for in evaluating for diabetic macular edema (DME) and/or DR?

**Dr. Gonzalez:** I am looking for anything that is going to help me determine whether or not a patient has clinically significant macular edema as the cause of reduced vision or whether the primary problem is macular ischemia. Because most studies of intravitreal anti-VEGF agents and steroids enrolled patients with center-involving macular edema, the hallmark findings would be intraretinal cysts with retinal thickening involving the central macula, with or without serous retinal detachment and with or without hard exudates (Figure 2).

On FA, I am looking for microaneurysms with leakage and areas of capillary nonperfusion (Figure 3). I also make sure there is no neovascularization both in the posterior pole or the periphery. With DME you basically look for dilated, altered capillaries in the macular region that leak over time resulting in diffuse or localized leakage of fluorescein. The reason that it is important to make this distinction is that this is what I use to determine which treatment I will use. If the edema is center-involving and meets the criteria in the studies I will initiate treatment with an anti-VEGF agent. If it is focal and not involving the central macula, then I use a light focal laser treatment.

### It sounds like you use imaging to guide your therapy decisions, and the results of imaging may steer you in one direction or another.

**Dr. Gonzalez:** I still use the clinically significant macular edema criteria from the original Early Treatment Diabetic Retinopathy Study as a factor in choosing therapy. If the edema is not center-involving, but if it holds and falls within that guidelines of the ETDRS, I use focal laser treatment. If the edema is center-involving, then I use an anti-VEGF agent or a steroid as the basis for treatment.

### Do you use imaging to determine response to treatment? What do you look for?

**Dr. Gonzalez:** Absolutely. Whether I am treating center-

involving DME or focal noncenter-involving DME, I use OCT. I look for a decrease in retinal edema, normalization of the retinal anatomy, and an improvement in visual acuity.

### Does what you look for on imaging differ at all depending on what type of therapy is being used (ie, anti-VEGF vs corticosteroid)?

**Dr. Gonzalez:** No, not really. All of the treatment modalities should give me a very similar type of change over time. Regardless of which agent I am using to treat the DME, I want to see a progressive decrease in the level of intraretinal fluid, normalization of the retinal anatomy, and an improvement in visual acuity.

### Do you treat toward anatomic resolution or functional correlates such as visual acuity change? Or do you use a combination of both?

**Dr. Gonzalez:** I use a combination of both. I want to see an improvement in visual acuity and an improvement in anatomic structure.

I will continue therapy even if the macular anatomy has normalized as long as the patient continues to come in with improving visual acuity. I start backing off treatment once I see that the anatomy is normalized and there is no visual improvement over 2 follow-up visits separated by at least a month. I obtain a BCVA in these patients when I am going to make decisions that entail cutting back on the medication.

### Are there any seminal or important studies in the literature that you refer to on the subject of imaging in patients with DME/DR?

**Dr. Gonzalez:** There are several I think are important. The DRCR.net Protocol I,<sup>1</sup> the ETDRS,<sup>2</sup> and the DRS.<sup>3</sup> Also RISE and RIDE,<sup>4</sup> and, more recently, VISTA and VIVID<sup>5</sup> and other studies with aflibercept (Eylea, Regeneron). I will be interested to see the results of the DRCR.net Protocol T. They will be very important. ■

*Victor H. Gonzalez, MD, is the founder of Valley Research Institute in McAllen, Texas. Dr. Gonzalez may be reached at [maculadoc@aol.com](mailto:maculadoc@aol.com).*



1. Elman MJ, Ayala A, Bressler NM, et al; The Diabetic Retinopathy Clinical Research Network. Intravitreal ranibizumab for diabetic macular edema with prompt versus deferred laser treatment: 5-Year randomized trial results. *Ophthalmology*. 2014 (Accepted).
2. Early Treatment Diabetic Retinopathy Study Research Group. Photocoagulation for diabetic macular edema: Early Treatment Diabetic Retinopathy Study report number 1. *Arch Ophthalmol*. 1985;103(12):1796-1806.
3. The Diabetic Retinopathy Study Research Group; Indications for photocoagulation treatment of diabetic retinopathy. Diabetic Retinopathy Study Report Number 14. *Invest Ophthalmol Clin* 1994;27:239-253.
4. Brown DM, Nguyen QD, Marcus DM, et al; RIDE and RISE Research Group. Long-term outcomes of ranibizumab therapy for diabetic macular edema: the 36-month results from two phase III trials: RISE and RIDE. *Ophthalmology*. 2013;120(10):2013-2022.
5. Do DV. Intravitreal aflibercept injection (IAI) for diabetic macular edema (DME): 12-month results of VISTA-DME and VIVID-DME. Paper presented at: the 2013 Annual Meeting of the American Academy of Ophthalmology; November 16-19, 2013; New Orleans, LA.