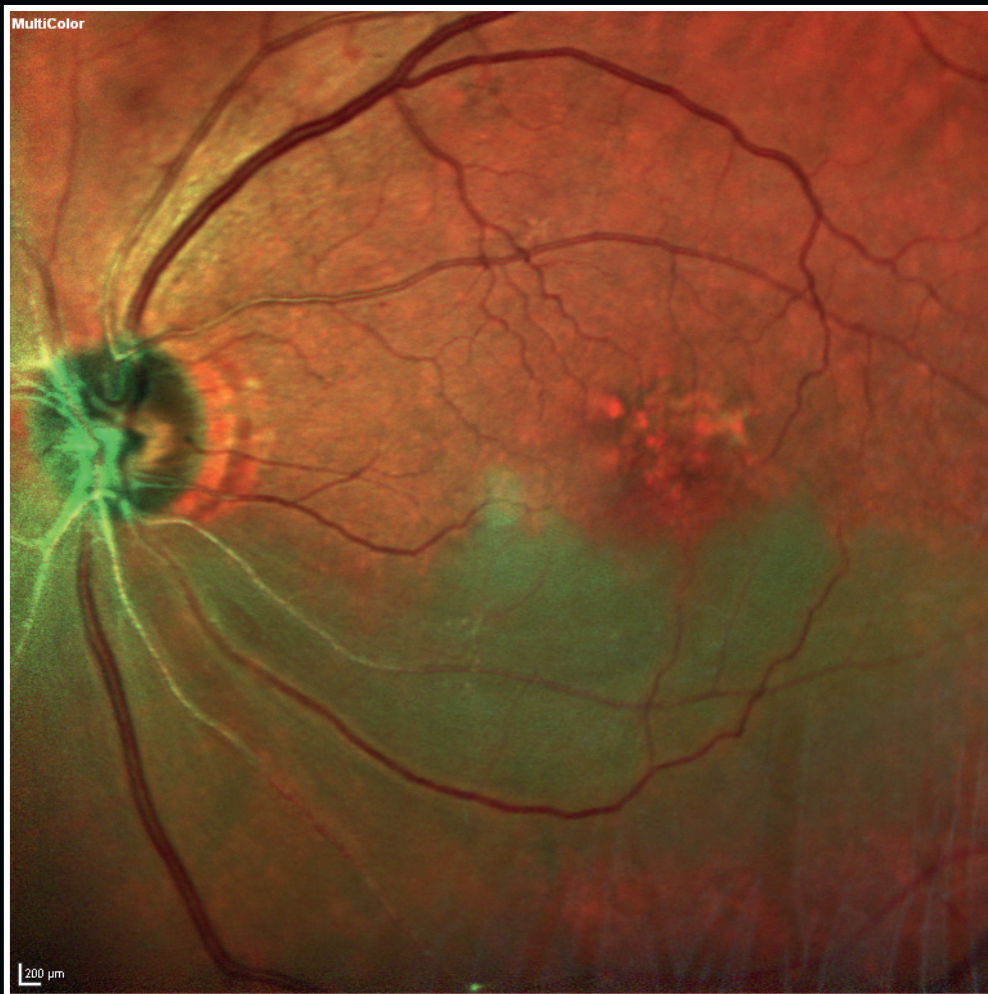

Heidelberg Engineering - SPECTRALIS® multicolor™

MultiColor ATLAS



Provided to you by:

**HEIDELBERG
ENGINEERING**

Foreword

As one of the first people to have been given the opportunity to use SPECTRALIS MultiColor, I am delighted to take on the role of Editor for this MultiColor Atlas. When I first used MultiColor, I knew that it was a Confocal Scanning Laser Ophthalmoscope (cSLO) that captured cSLO fundus images at three different wavelengths. I thought the only new feature of the device was that it could offer information specific to each layer of the retina (i.e. surface, medium and deep layers), depending on the characteristics of each of the three wavelengths. When I saw how different the first fundus image I took using MultiColor was from that taken using a traditional fundus camera, I felt so uneasy that I wasn't sure I could use this new machine. However, since then I have viewed many more MultiColor images and I have completely changed my mind. A traditional fundus camera captures all of the reflected light that enters the eye to produce an image, which means that light diffracted by the ocular media and unnecessary back scatter of light is included in the image. This results in reduced contrast. MultiColor, on the other hand, produces a composite fundus image that displays data from the chorio/retinal structure and suppresses unwanted scattered light. I believe this is a major advantage over traditional fundus cameras.

If you compare retinal images taken using MultiColor with those taken using Optical Coherence Tomography (OCT), you will find that the regions colored as abnormal in the MultiColor images are largely consistent with the abnormal sites in the OCT images. This, in addition to the fact that MultiColor offers superior identification of avascular areas that are visible in angiography, has led me to believe that MultiColor offers more than just a conventional fundus image. MultiColor could change the traditional style of outpatient care by allowing us to observe minor changes in patients with disease at an earlier stage, particularly in the posterior of the fundus. It may also allow for more accurate diagnosis. There is still much to learn about the color display used in MultiColor fundus imaging.

In producing this Atlas, we hope to explain these points by presenting as many different images as possible. We hope that by doing so, many more physicians will recognize the potential of SPECTRALIS MultiColor. We also hope to further the study of MultiColor fundus imaging.



Editor: Dr. Shozo Sonoda, Associate Professor of Medicine
Department of Ophthalmology, Kagoshima University Graduate School of Medical and
Dental Sciences

On the front cover:

A case of inferior Retinal Artery Occlusion (RAO) in a 65-year old female. MultiColor fundus image taken immediately after onset, in which abnormal vessels are represented in white (vascular sheathing) and infarcted regions are depicted in green, resulting from acute inner retinal edema (these would appear highly reflective in an Optical Coherence Tomography (OCT) image.)

Contents

1. Principles and Features of MultiColor

Confocal Scanning Laser Ophthalmoscopy (cSLO)	4
Lasers of Three Different Wavelengths	5
MultiColor Imaging in Practice	6

2. MultiColor: Case studies

Epiretinal Membrane (ERM)	7
1. Epiretinal Membrane (ERM)	7
2. Epiretinal Membrane (ERM)	8
Glaucoma	9
3. Glaucoma.....	9
4. Glaucoma.....	10
Age-related Macular Degeneration (AMD)	11
5. Early AMD	11
6. Polypoidal Choroidal Vasculopathy (PCV).....	12
7. Soft drusen.....	13
8. Reticular pseudo-drusen	14
9. Polypoidal Choroidal Vasculopathy (PCV).....	15
Retinal Pigment Epithelitis	16
10. Retinal Pigment Epithelitis	16
Central Retinal Artery Occlusion (CRAO)	17
11. Central Retinal Artery Occlusion (CRAO)	17
Retinal Vascular Occlusion (RVO)	18
12. Branch Retinal Vein Occlusion (BRVO)	18
13. Branch Retinal Vein Occlusion (BRVO)	19
14. Central Retinal Vein Occlusion (CRVO).....	20
15. Branch Retinal Vein Occlusion (BRVO)	21
Diabetic Macular Edema (DME)/ Diabetic Retinopathy (DR)	22
16. Diabetic Macular Edema (DME)	22
17. Diabetic Macular Edema (DME)	23
18. Diabetic Retinopathy (DR).....	24, 25
19. Diabetic Retinopathy (DR).....	26
Retinal Vascular Occlusion (RVO)	27
20. Retinal Vascular Occlusion (RVO)	27
Macular Hole (MH)	28
21. Post Macular Hole (MH) Surgery	28
Article: MultiColor and Observation of the Retinal Vessels.....	29

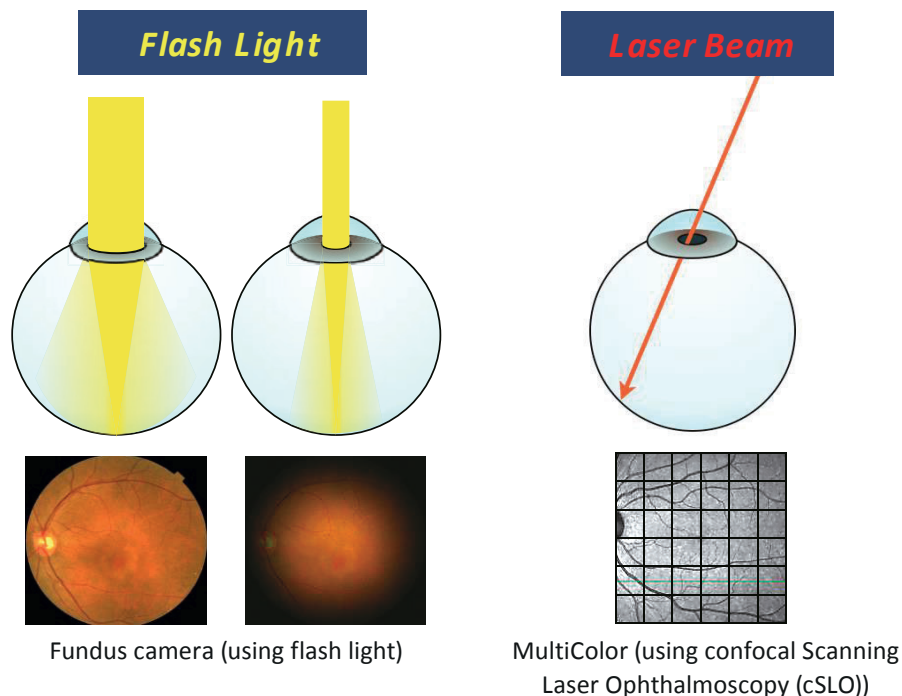
Principles and Features of MultiColor

MultiColor is an option of SPECTRALIS and has the following features.

Confocal Scanning Laser Ophthalmoscopy (cSLO)

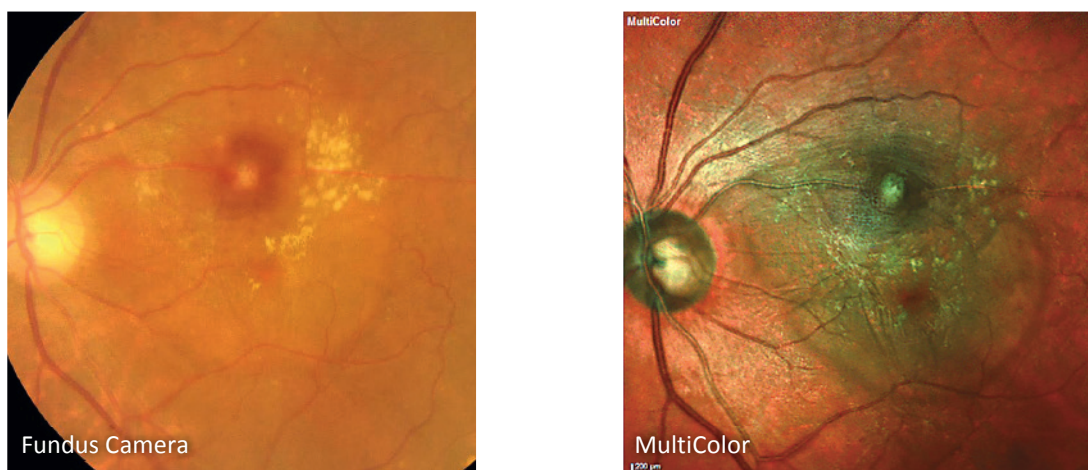Conventional fundus cameras expose the entire retina to white light with its broad spectrum and capture all of the reflected light as an image. This can result in a blurry image since scattered light is captured at the same time. In addition, differences in pupil diameter have a major effect on the light that reaches the fundus.

MultiColor, on the other hand, captures the image by way of Confocal Scanning Laser Ophthalmoscopy (cSLO), using a laser scan comprising of three wavelengths, infrared (815nm), green (514nm) and blue (488nm). The confocal technology only captures reflected light passing through a pinhole, which allows for a high-quality, high-contrast image. The resulting image is less affected by scattered light and light from outside the focal plane.



Comparison of MultiColor and Fundus Camera Images: a case of retinal macroaneurysm

The image captured using MultiColor is very different to that captured using a traditional fundus camera.

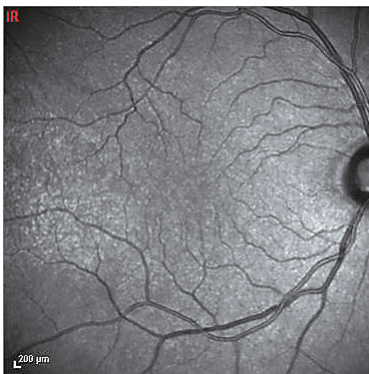


Principles and Features of MultiColor

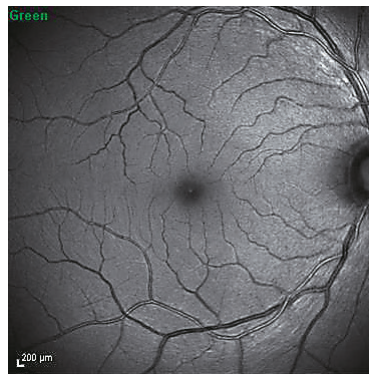
Lasers of Three Different Wavelengths

In addition to the use of Confocal Scanning Laser Ophthalmoscopy as described above, it is possible to capture SLO images at three different levels of penetration into the retina since MultiColor uses lasers of three different wavelengths. The laser wavelength enhances each separate layer, with the surface of the retina captured by the short wavelength (486 nm), the retinal vascular and inner retinal layers by the medium wavelength (518 nm), and the retinal pigment epithelium (RPE) and other deep layers by the long wavelength (815 nm). The MultiColor fundus image is a composite of all three.


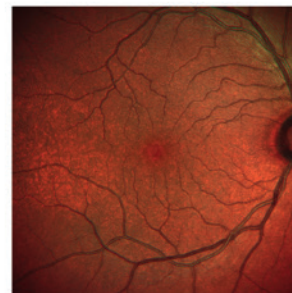
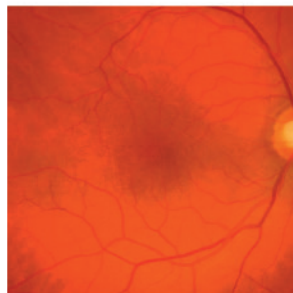
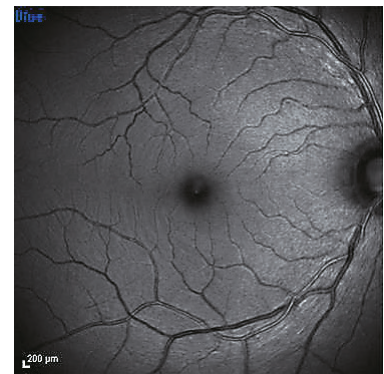
Infrared : 815 nm



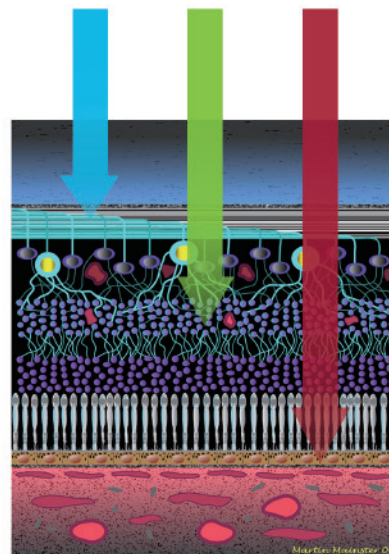
Green : 518 nm



Blue : 488 nm



Fundus Camera

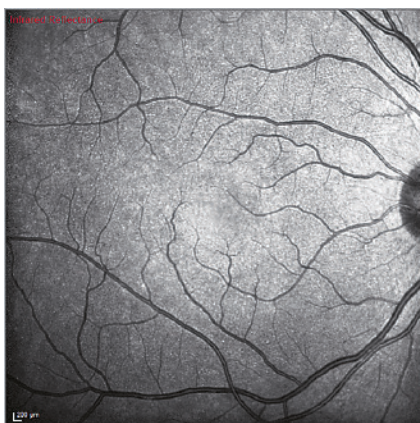
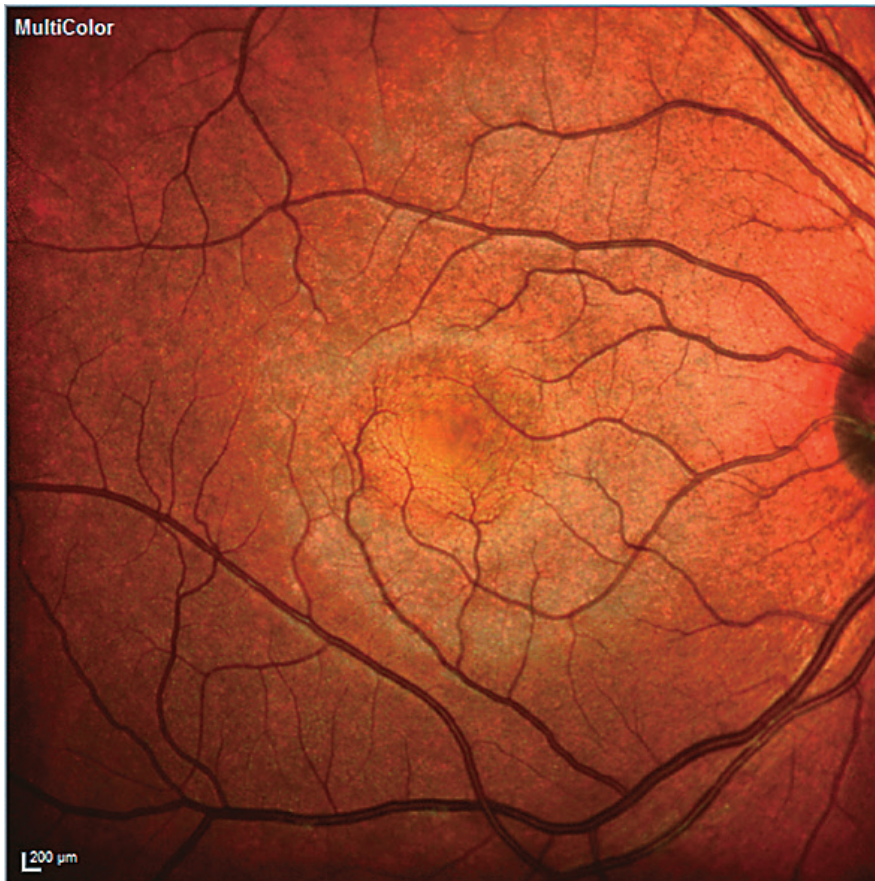
MultiColor Fundus Image

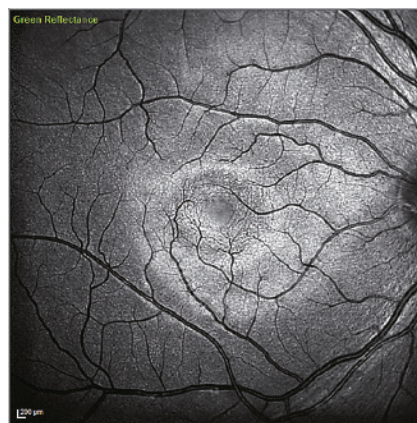Principles and Features of MultiColor

MultiColor Imaging in Practice

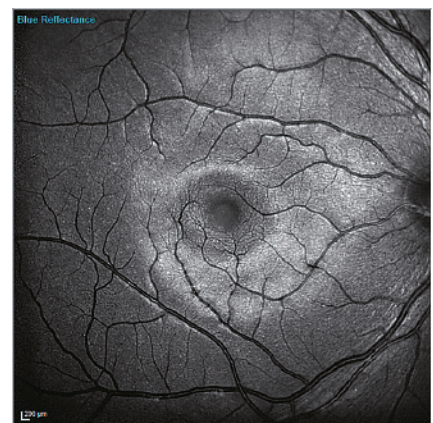Composite image from three wavelengths: MultiColor Fundus Image



Infrared: RPE level



Green: Retinal vessels

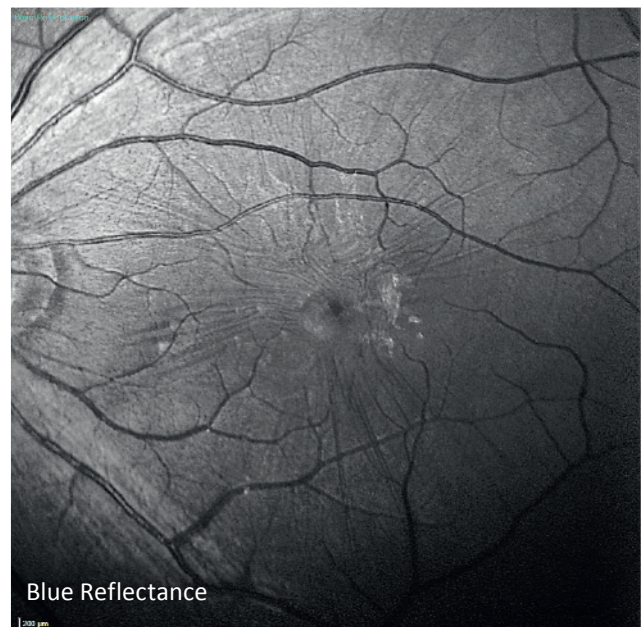
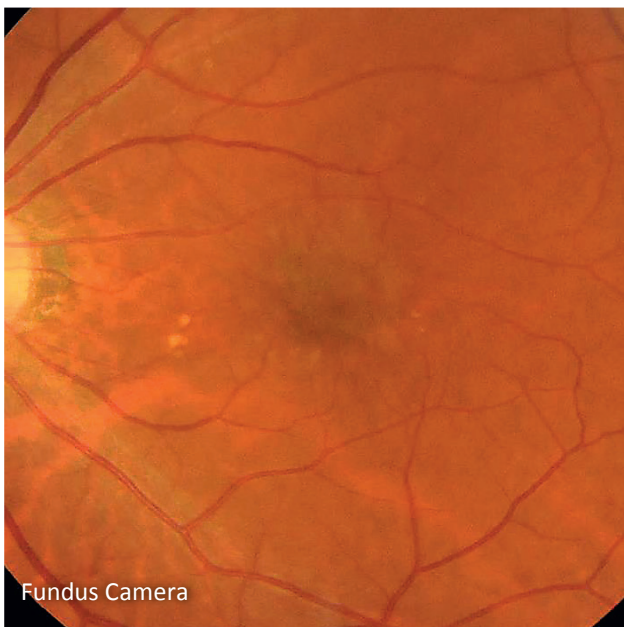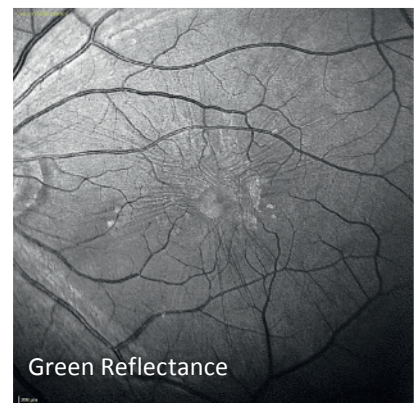
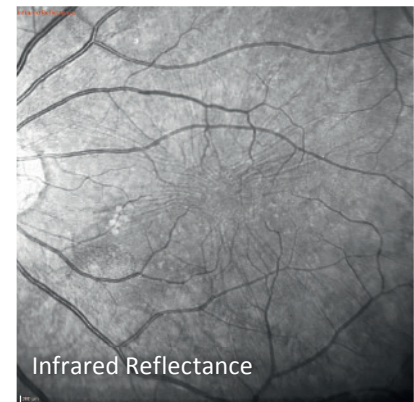

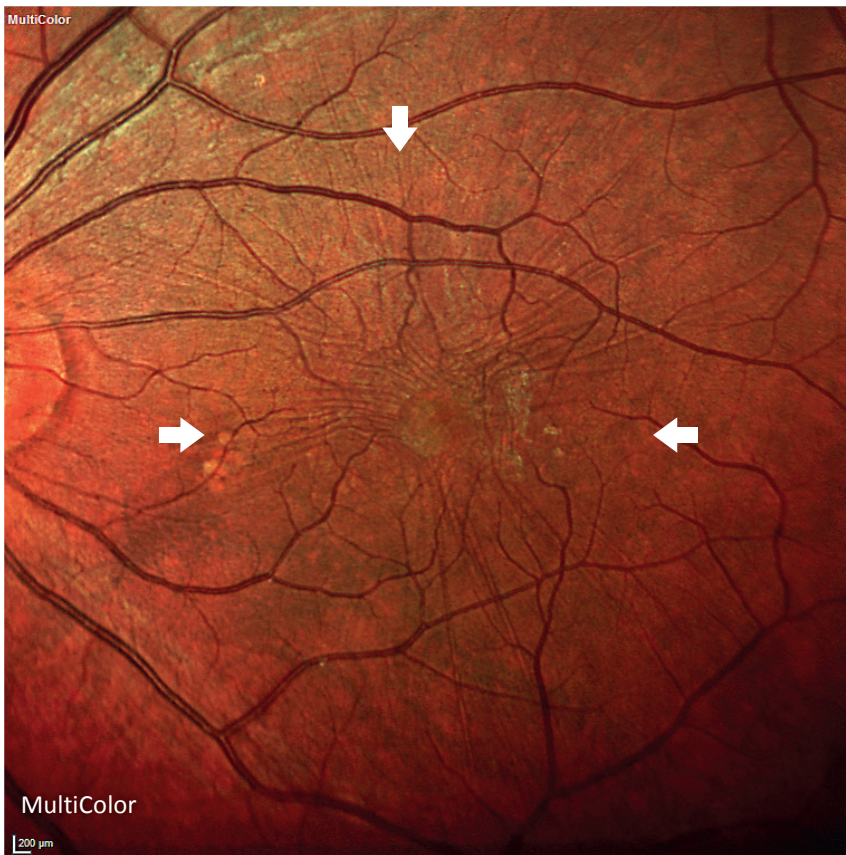
Blue: Retinal Surface

MultiColor produces an image of higher contrast than a traditional fundus image, and the vessels in the macular region are more clearly defined. The MultiColor image should be interpreted by reading each of the three original SLO images individually. However, once you are accustomed to interpreting MultiColor images, it is possible to simply use the MultiColor composite image. Traditional fundus cameras capture all reflected light that enters the eye, which means that signals from outside the area of examination appear in the image. On the other hand, MultiColor only enhances the signals for the area of examination, which allows for easier interpretation of the image.

Epiretinal Membrane (ERM)

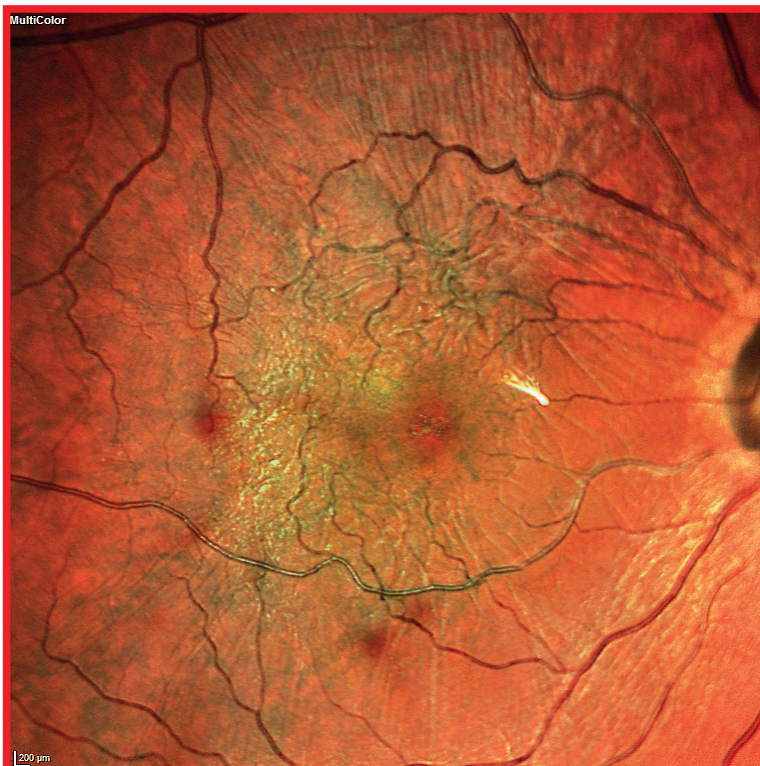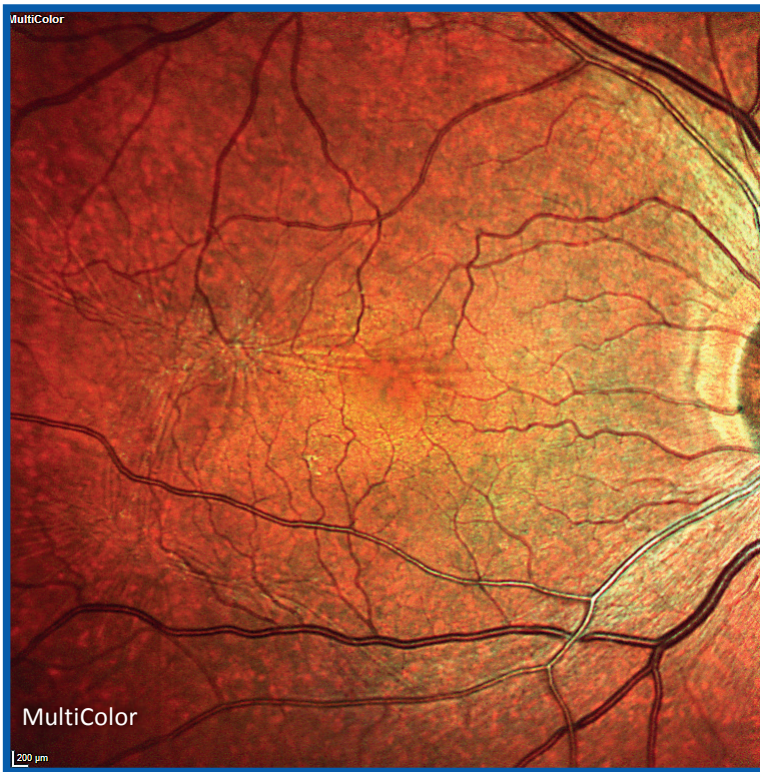
1. Epiretinal Membrane (ERM)



61 year-old female. The full extent of the ERM is more clearly evident in the MultiColor fundus image (arrows) than in the conventional fundus image. The blue reflectance image provides the best view of the surface layer. The ERM is more clearly evident in the blue reflection than in the infrared reflection image.

Epiretinal Membrane (ERM)

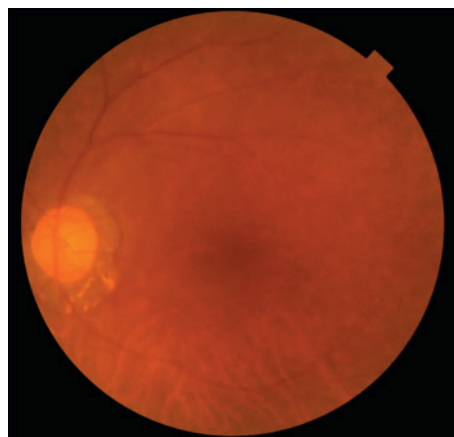
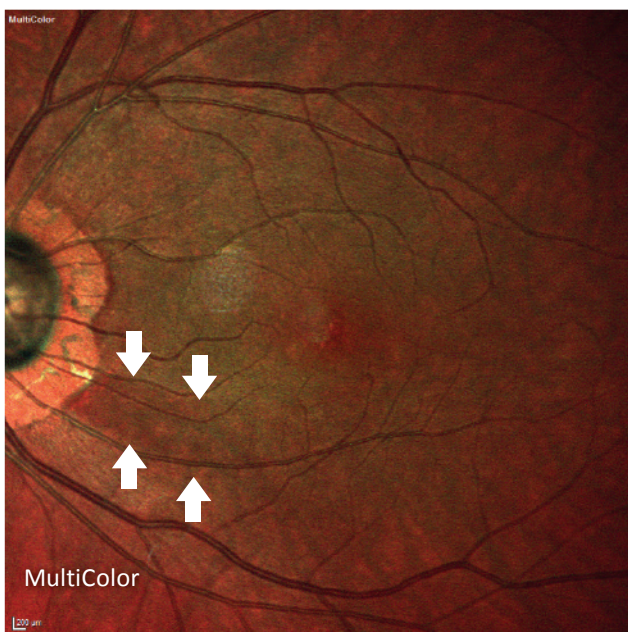
2. Epiretinal Membrane (ERM)



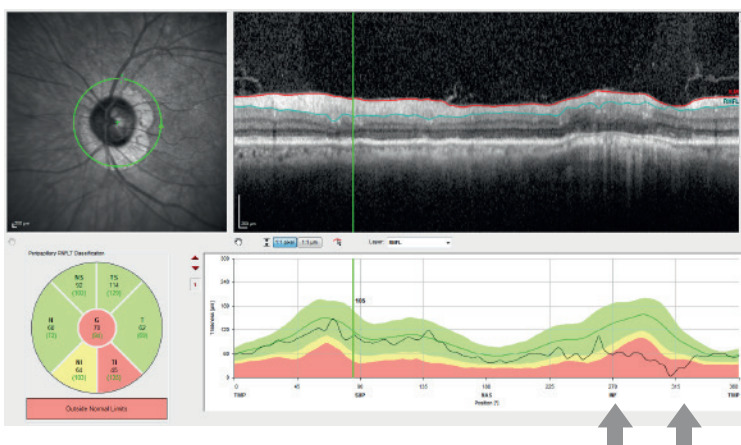
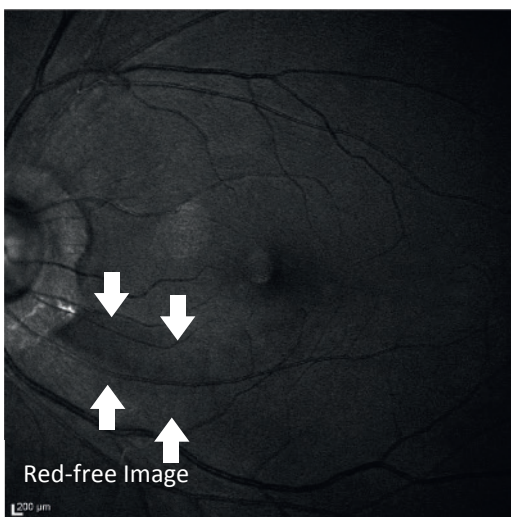
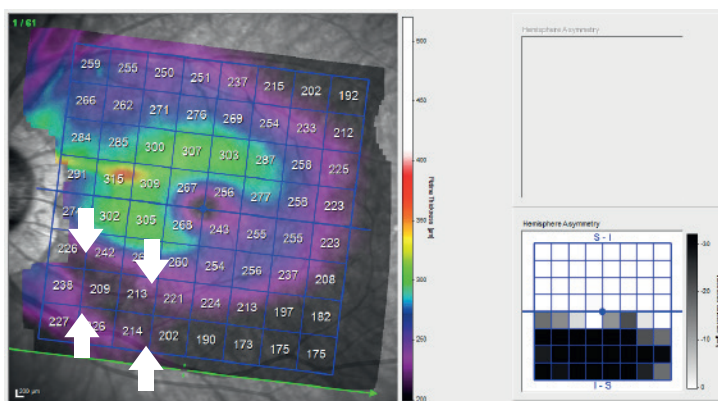
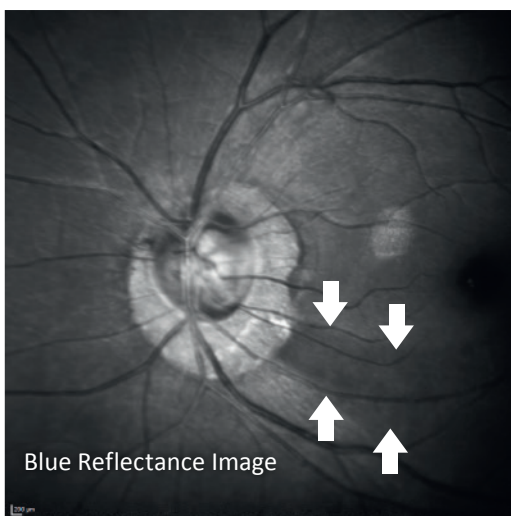
The scope of the ERM and the changes are clearly captured in the MultiColor fundus image.

Glaucoma

3. Glaucoma



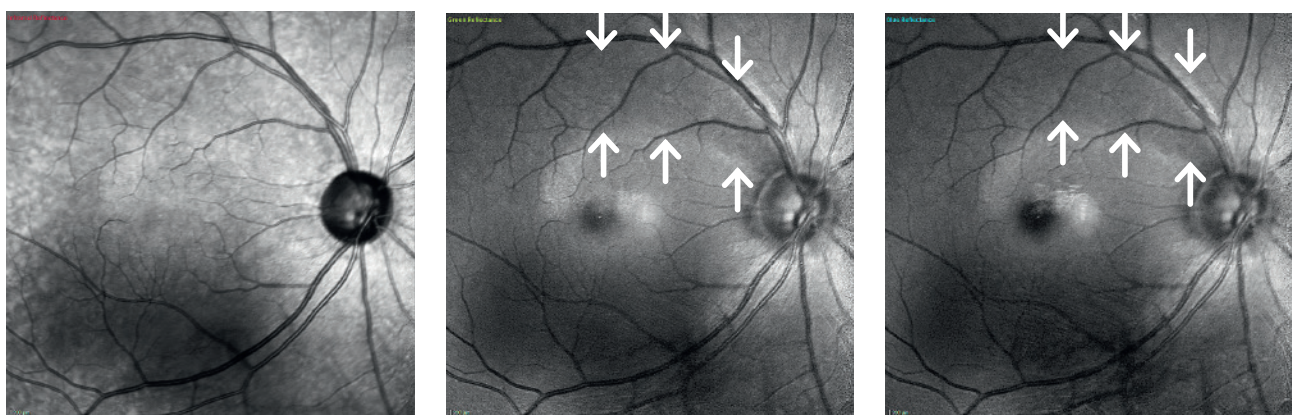
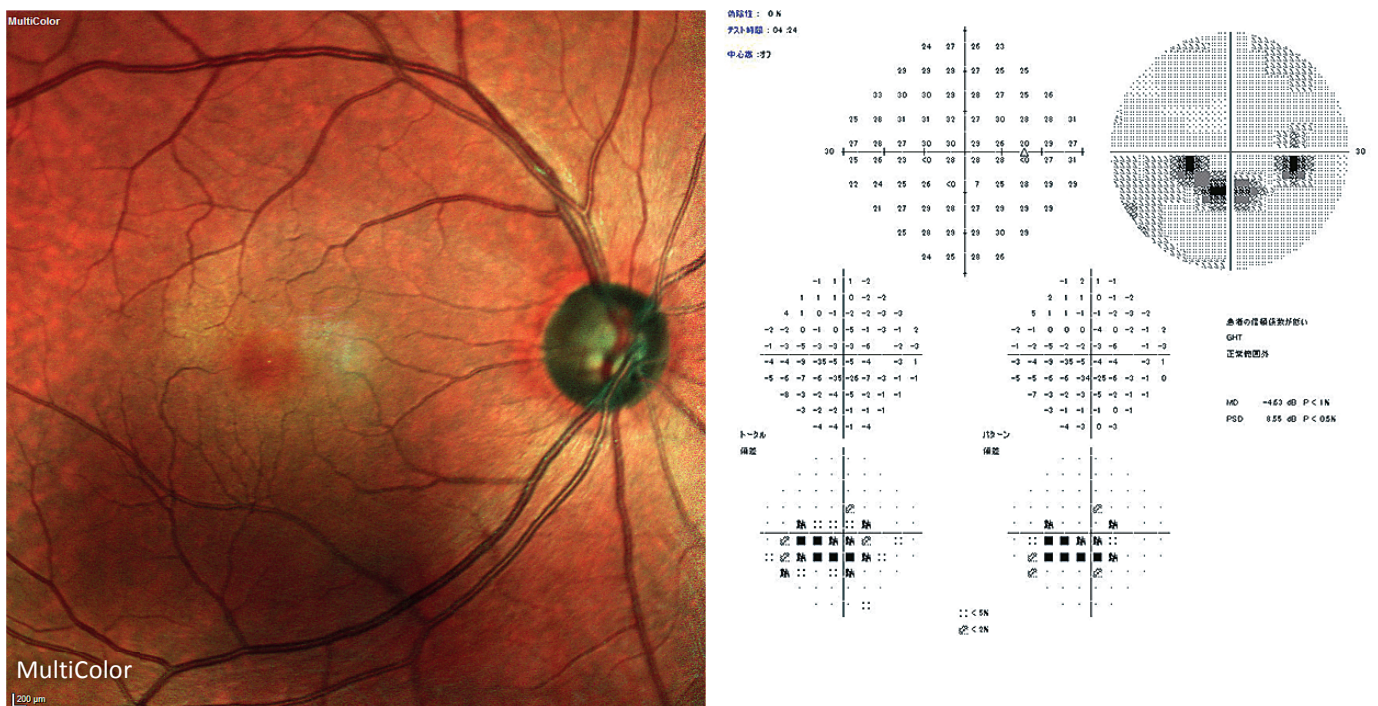
Regular Fundus Image



Glaucoma

(Previous page) **77-year old female.** The nerve fiber layer defect (NFLD) is not visible in the regular fundus image but MultiColor provides a high contrast fundus image. Regular fundus images are extremely useful in diagnosing glaucoma but MultiColor is less affected by cataracts, which allows for more accurate interpretation. The use of short and medium MultiColor wavelengths are useful since NFLDs cause changes to the surface layers of the retina. The NFLD is clearly observed in temporal-interior side on both RNFL thickness map and Posterior Pole Analysis and it is consistent with MultiColor fundus image. The green reflectance within the MultiColor is the same wavelength used for red-free images that have proven useful in identifying NFLDs. Since this medium wavelength can replace the need to take additional red-free images, it makes MultiColor a very efficient test.

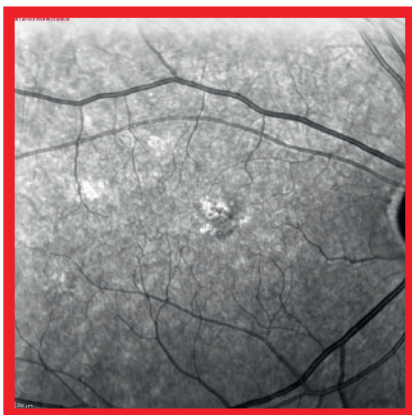
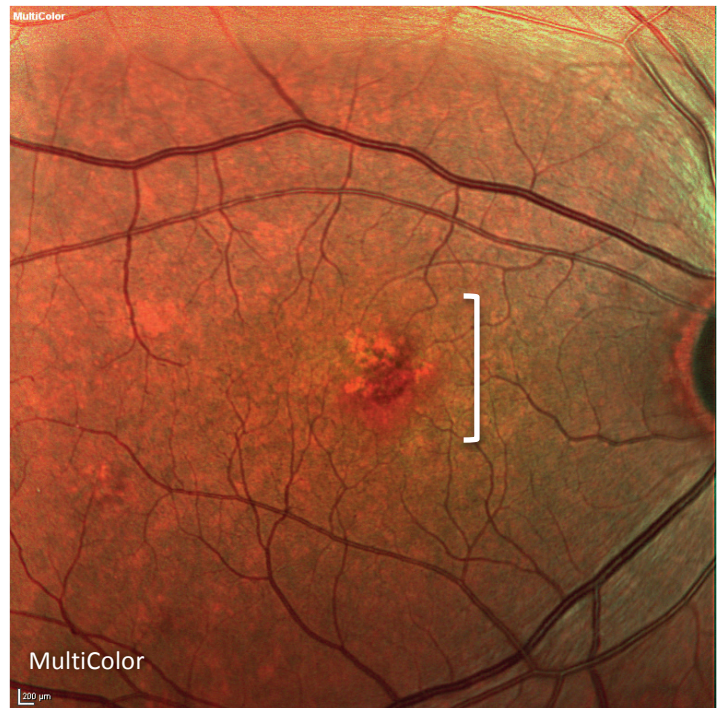
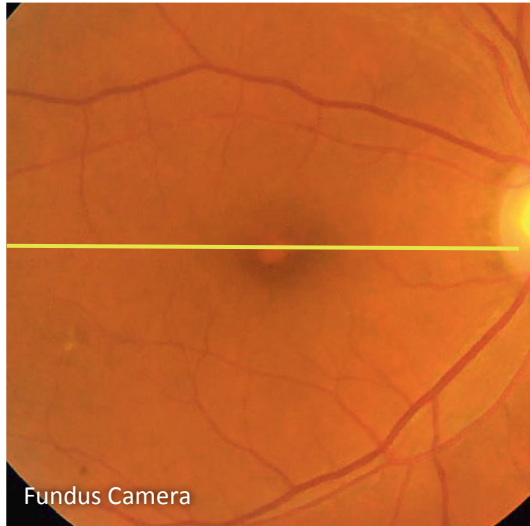
4. Glaucoma



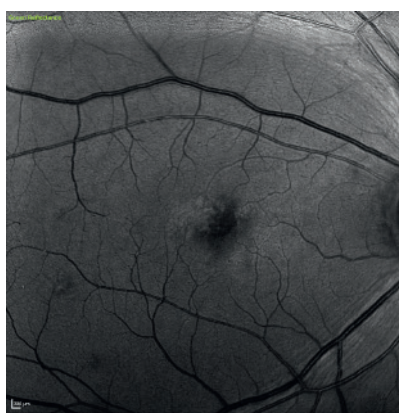Another case of Glaucoma in a 59-year old female. The NFLD is clearly evident in the short and medium wavelength MultiColor SLO images. The NFLD observed in the MultiColor fundus image is largely consistent with the results of the Humphrey Visual Field Analysis.

Age-related Macular Degeneration (AMD)

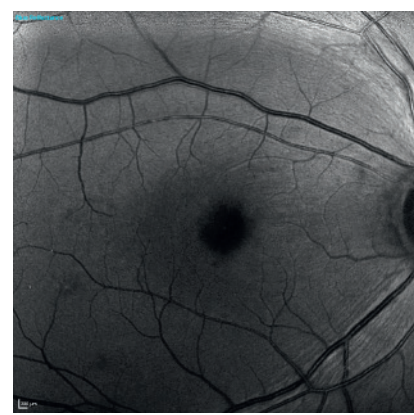5. Early Age-related Macular Degeneration (AMD)



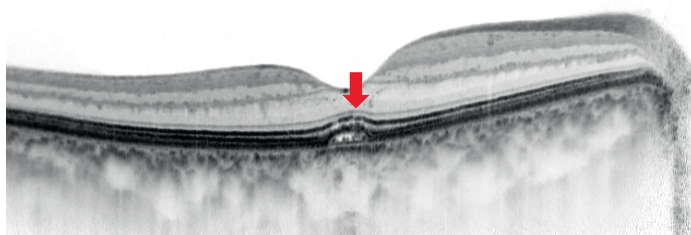
Infrared: RPE level



Green: Retinal vessels



Blue: Retinal Surface



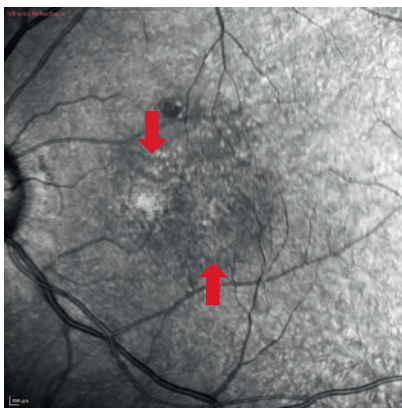
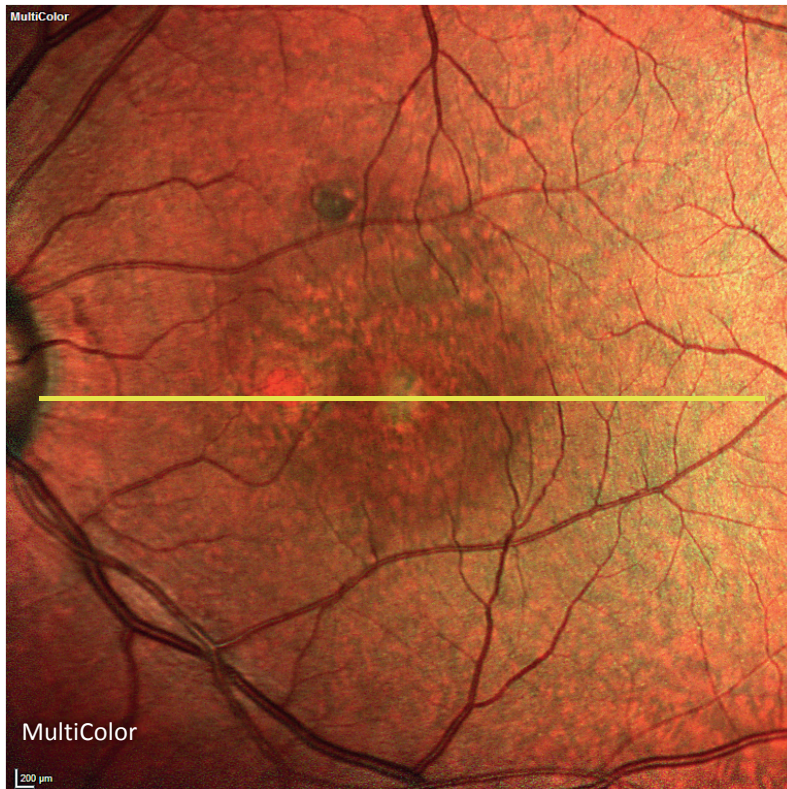OCT image

A case of early age-related macular degeneration (AMD) in a 54-year old male.

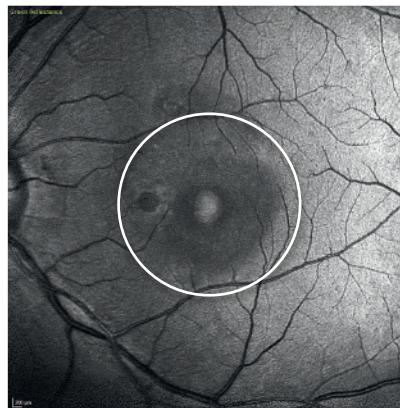
The abnormal regions of the retinal pigment epithelium (RPE) are more clearly defined in the MultiColor fundus image (bracket) than the regular fundus image. The abnormal regions of the RPE observed here are largely consistent with those observed in the OCT image (arrow). The long wavelength SLO image (red box) shows the abnormal regions of the RPE.

Age-related Macular Degeneration (AMD)

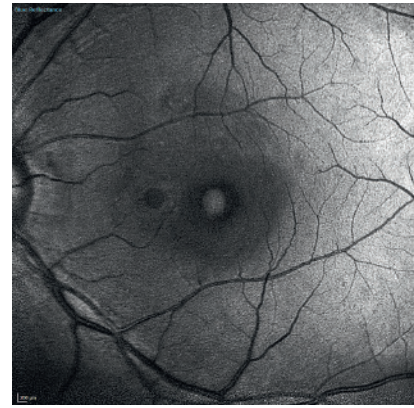
6. Polypoidal Choroidal Vasculopathy (PCV)




Infrared: RPE level



Green: Retinal vessels



Blue: Retinal Surface



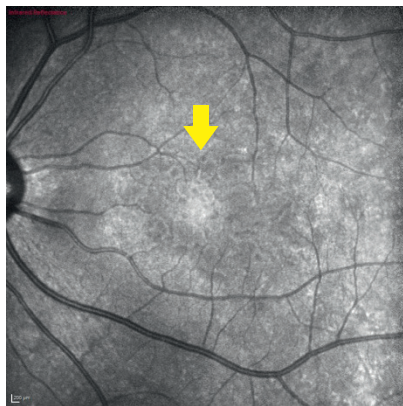
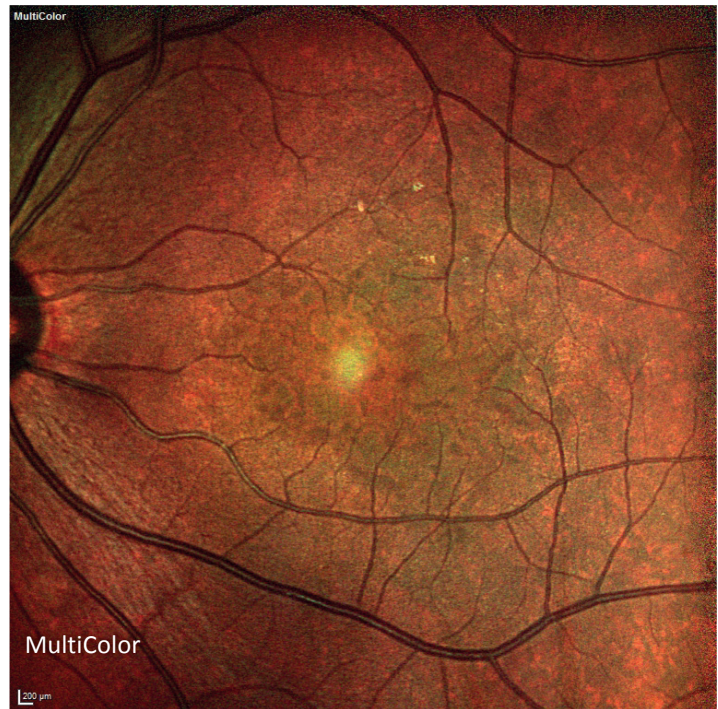
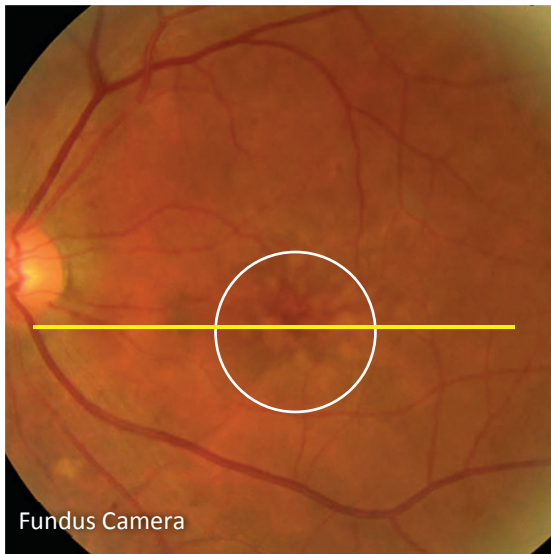
OCT image

A case of polypoidal choroidal vasculopathy (PCV) in a 70-year old male.

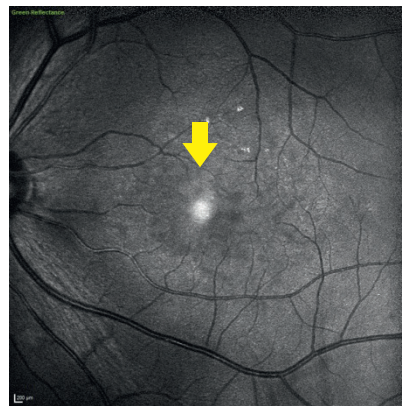
The MultiColor fundus image is largely consistent with the OCT image. In the OCT image, there is increased reflection in the raised areas caused by polyps (arrows). The shape of the serous retinal detachment is largely consistent with the medium wavelength SLO image (white circle).

Age-related Macular Degeneration (AMD)

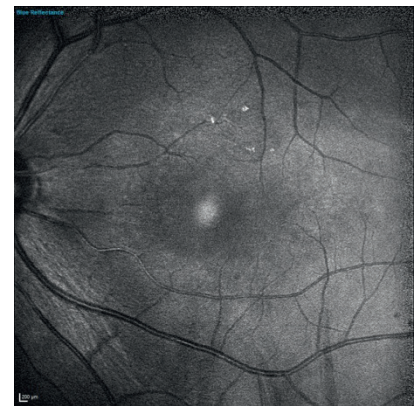7. Soft drusen



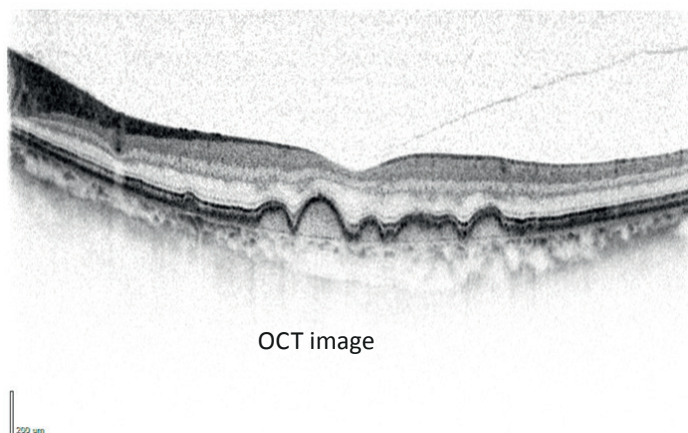
Infrared: RPE level



Green: Retinal vessels



Blue: Retinal Surface

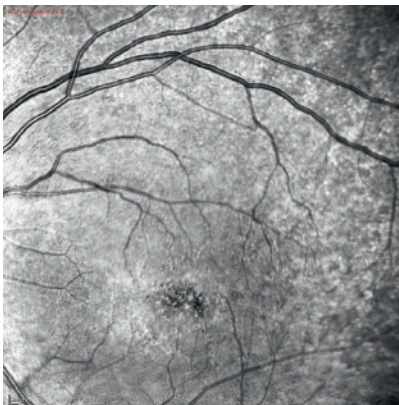
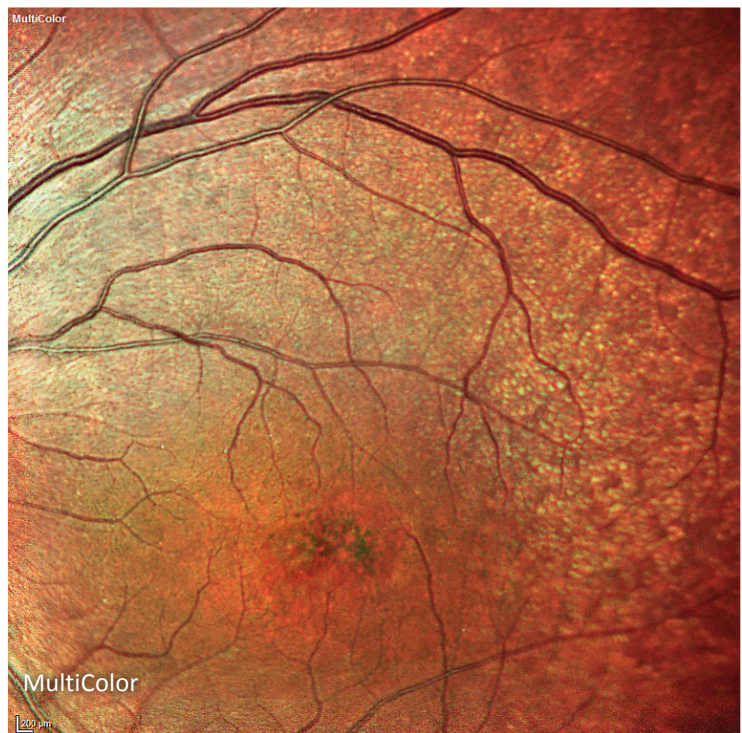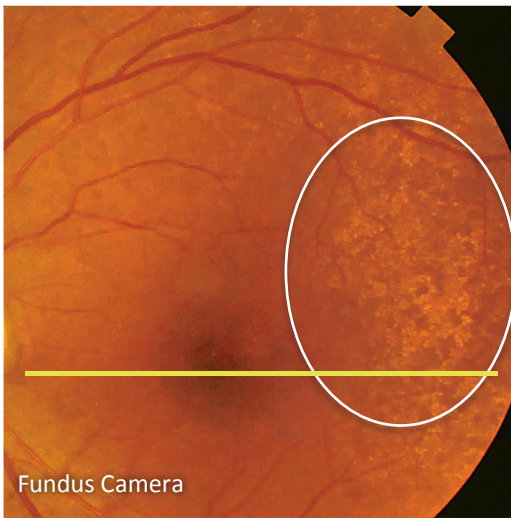


A case of drusenoid RPE detachment (soft drusen) in a 67-year old male.

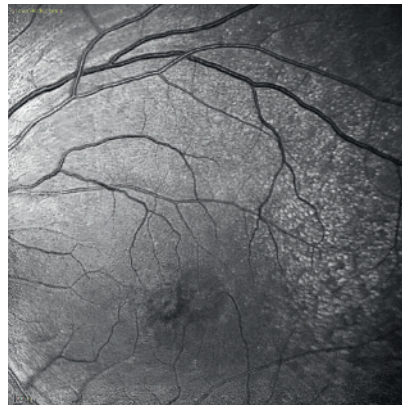
Drusen can be seen in the MultiColor fundus image, consistent with the conventional fundus image and OCT image (circle). Drusen are identified in the long and medium wavelength SLO images (arrow). Unlike the reticular pseudo-drusen on the following page, there are no intense reflections using the short wavelength. This may reflect the drusen site of deposition.

Age-related Macular Degeneration (AMD)

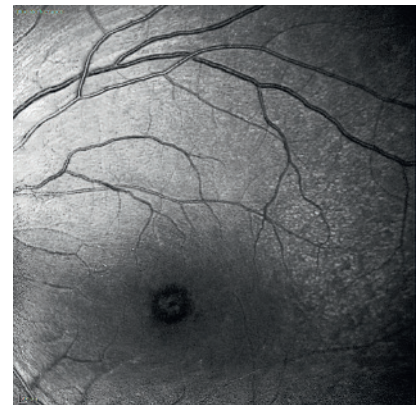8. Reticular pseudo-drusen



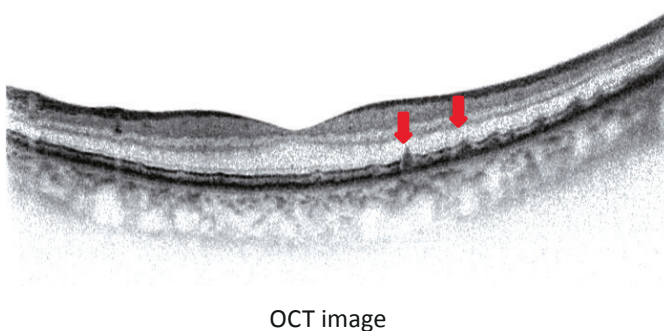
Infrared : RPE level



Green : Retinal vessels



Blue : Retinal Surface

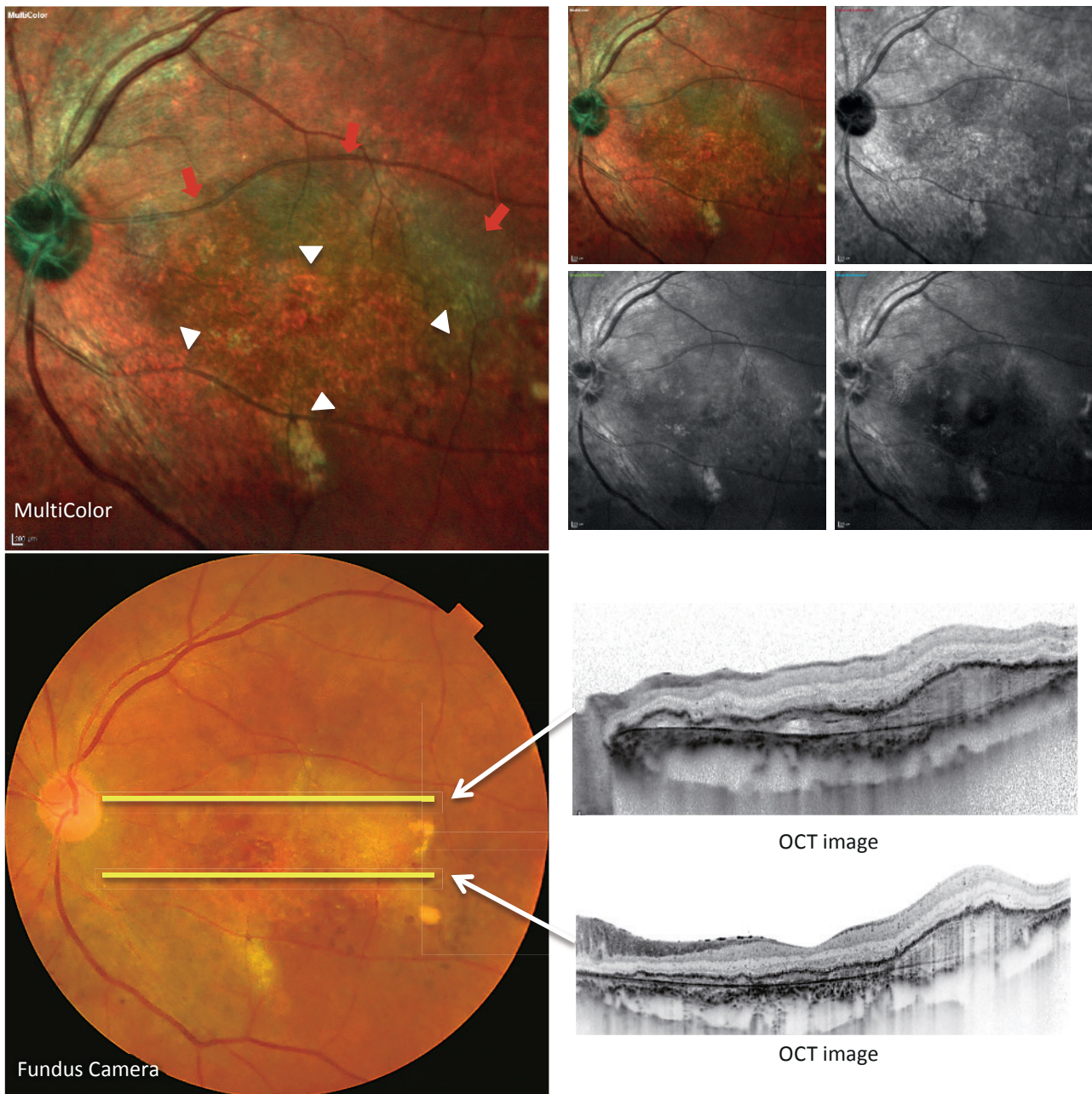


A case of reticular pseudo-drusen in a 70-year old female.

Unlike ordinary drusen, the site of deposition for reticular pseudo-drusen is on the inner border of the retinal pigment epithelium (RPE) (arrow): therefore, confirmation of the site of deposition with OCT and autofluorescence (the drusen site is hyperfluorescent in autofluorescence imaging) are useful for diagnosis. Unlike in the previous case, the deposits visible in the conventional fundus image (circle) and appear hyper reflective in the short and medium wavelength SLO images.

Age-related Macular Degeneration (AMD)

9. Polypoidal Choroidal Vasculopathy (PCV)



A 74-year old male.

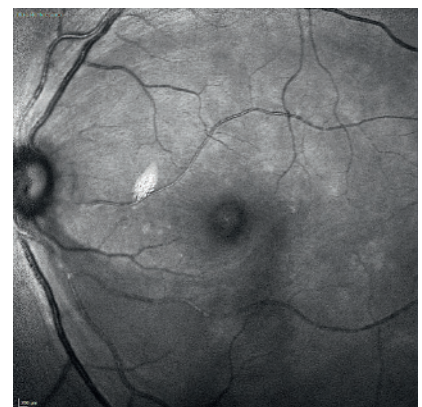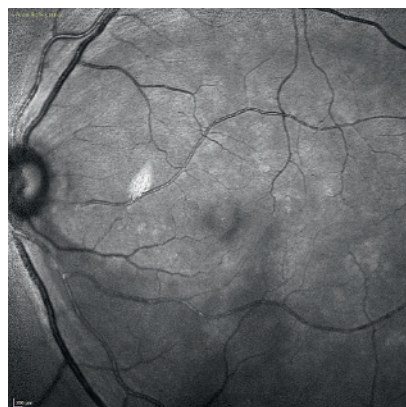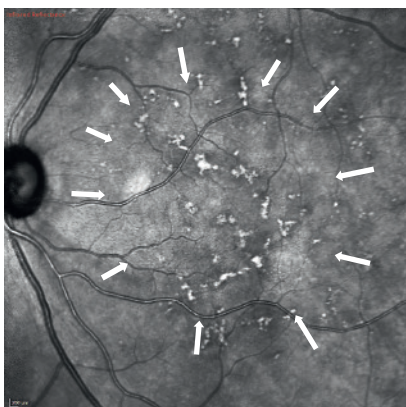

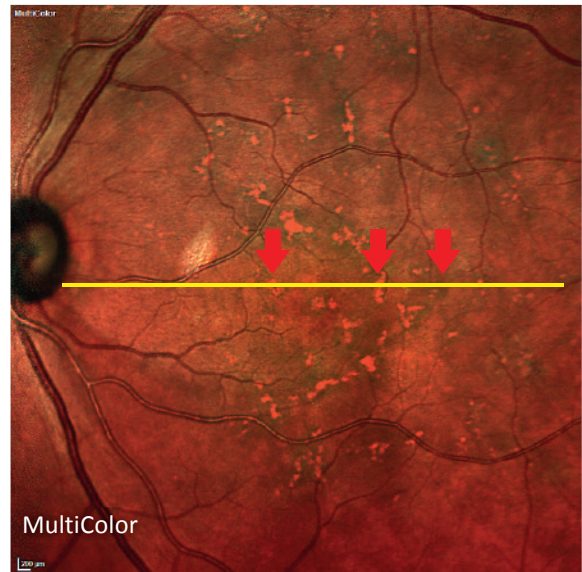
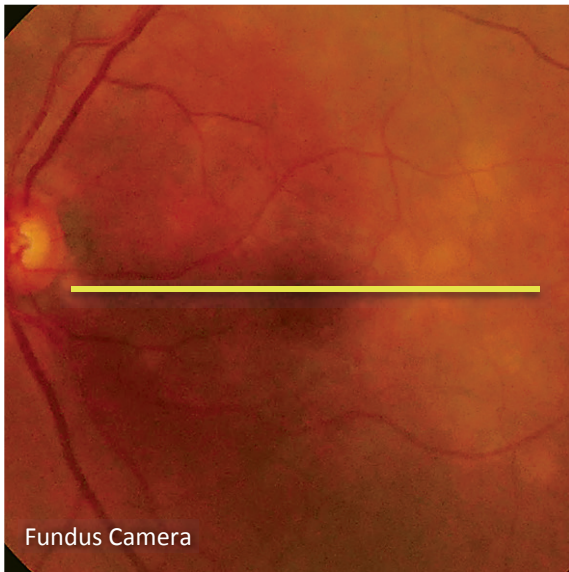
The fundus camera image and MultiColor fundus image are rather different.

If you compare the MultiColor image with the OCT image, the intensity of the green color in the MultiColor image varies depending on the height of the raised areas of the retinal RPE and sub-retinal/RPE fluid (arrows). In areas of high levels of RPE atrophy, there is a stronger signal (which is displayed as red enhancement in a MultiColor fundus image) since the long wavelength SLO laser reaches a deeper level.

The red coloring is therefore more intense, as in the case of retinal pigment epithelitis on the next page (arrowhead). This case suggests that, in the same way as OCT, it is possible that further analysis of the color display in MultiColor fundus images can be used to predict the structural changes to the retina.

Retinal Pigment Epithelitis

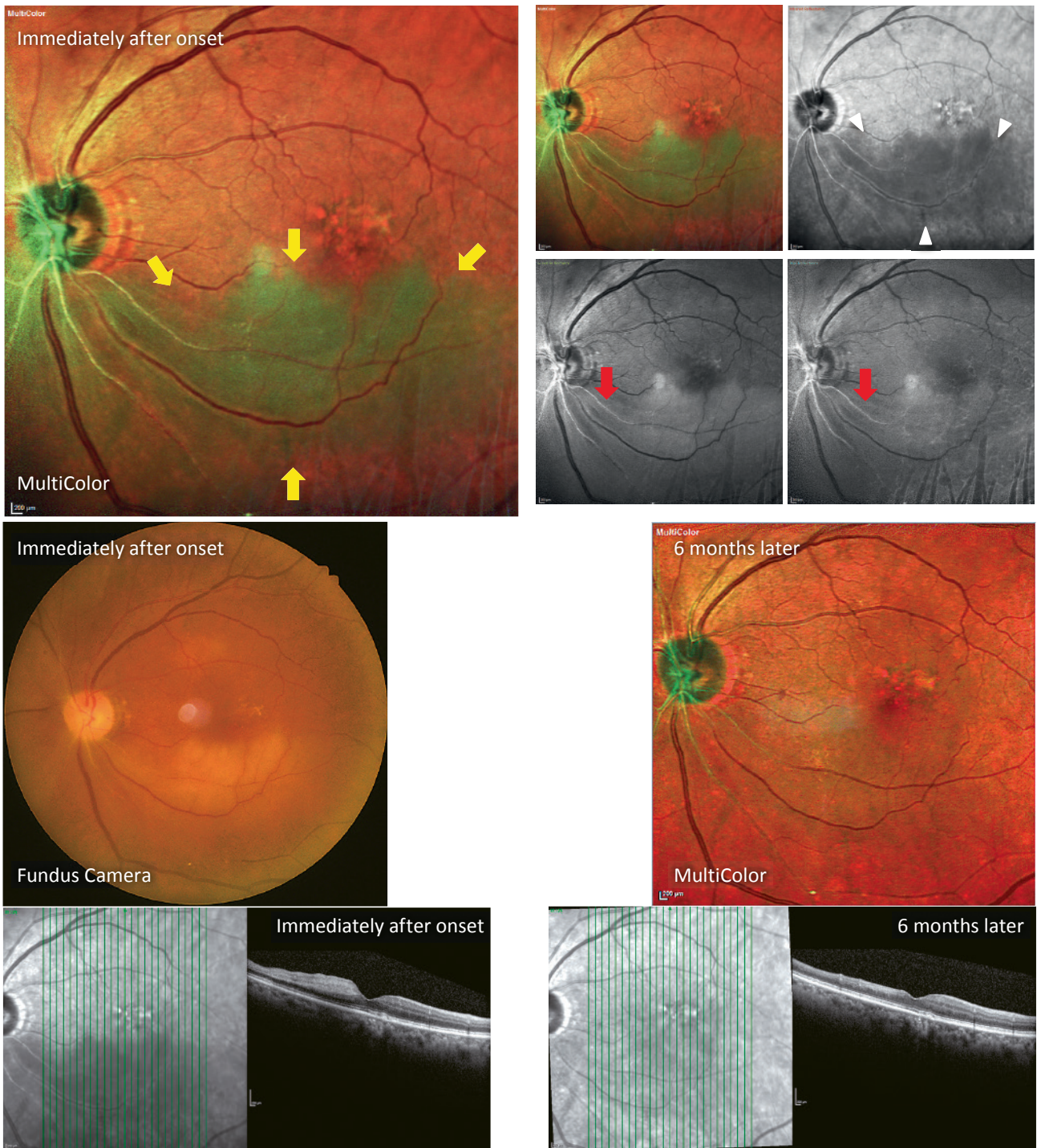
10. Retinal Pigment Epithelitis



Scar stage in a diagnosis of retinal pigment epithelitis in a 71-year old female. The abnormal regions are displayed in greater contrast in the MultiColor image than in the regular fundus image. In the OCT image, the disseminated RPE is seen as an increase in protrusions (red arrows). These are largely consistent with the disseminated abnormal pigment epithelium sites in the MultiColor fundus image. There are no major changes in the short or medium wavelength SLO images, but abnormal RPE sites are clearly evident in the long wavelength image (white arrows).

Central Retinal Artery Occlusion (CRAO)

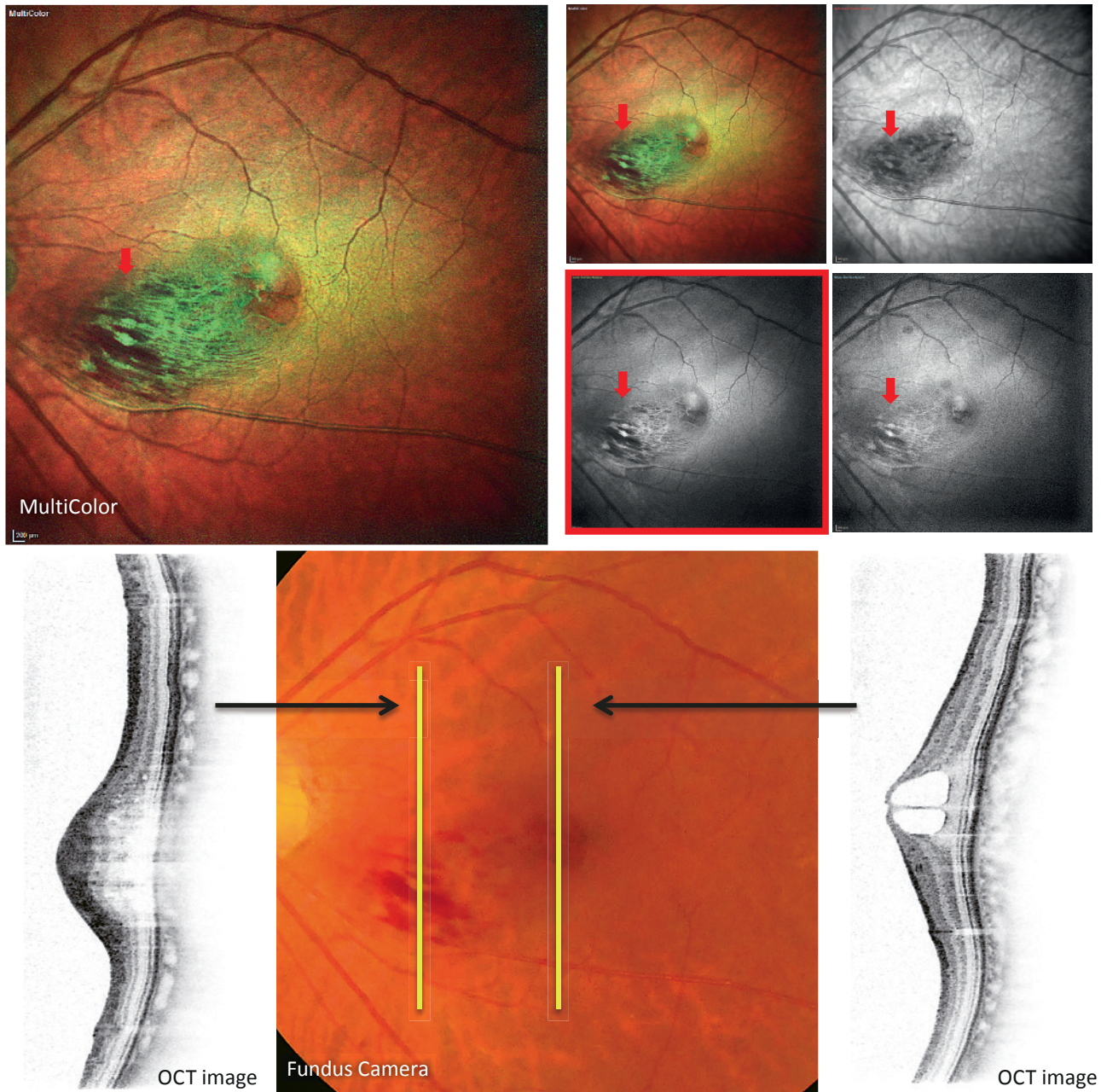
11. Central Retinal Artery Occlusion (CRAO)



A case of inferior central retinal artery occlusion (CRAO) in a 65-year old female. In a MultiColor fundus image taken immediately after onset, the abnormal vessels appear in white (short and medium wavelength SLO images (red arrows)). The highly reflective infarcted areas in the OCT show edema of the inner retina, the corresponding areas in the MultiColor fundus image appear green (white arrows). It is thought that retinal edema causes absorption of the infrared wavelength and increased reflection of the medium wavelength in the SLO image. (white arrowheads). In a MultiColor fundus image taken six months later, the green coloring (seen in the image taken immediately after onset) has disappeared. The edema has also disappeared in the OCT image.

Retinal Vascular Occlusion (RVO)

12. Branch Retinal Vein Occlusion (BRVO)

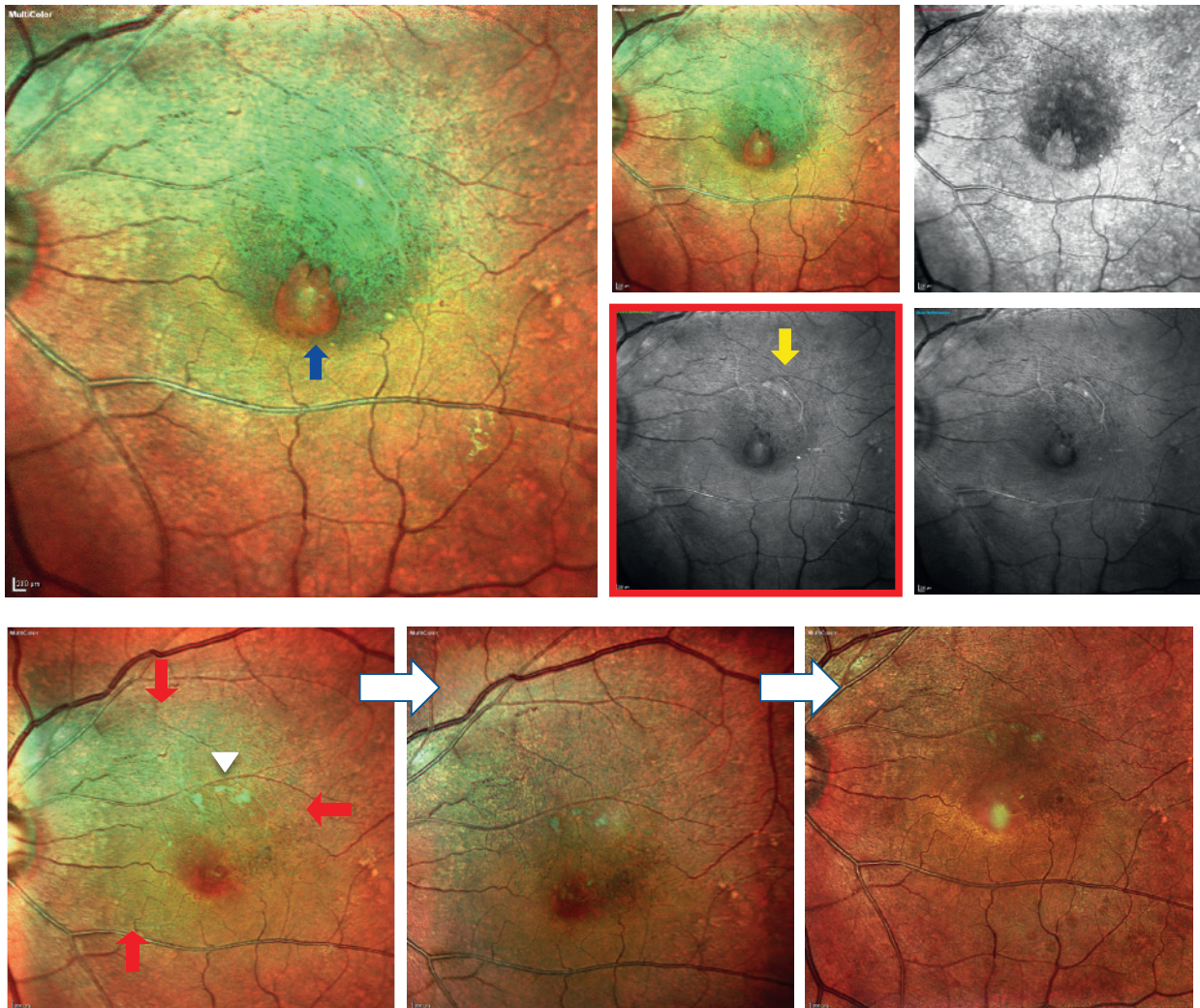


Left eye of a 65-year old male. Corrected visual acuity of 0.7.

I believe that retinal vascular occlusion (RVO) is one of the conditions in which MultiColor fundus imaging is at its most effective. Green enhancement shows edema in the inner layers of the retina and cotton wool spots (CWS, microinfarcts)(red arrows). The CWS is also enhanced in the short and medium wavelength SLO image (outlined in red above). The morphology of the edema in the retinal nerve fiber layer is also clearly evident. The cyst is unclear in the regular fundus image (bracket), but appears clearly in the MultiColor fundus image. The edema site and cyst morphology are displayed in colors to distinguish them from normal tissue, in contrast with the OCT image.

Retinal Vascular Occlusion (RVO)

13. Branch Retinal Vein Occlusion (BRVO)



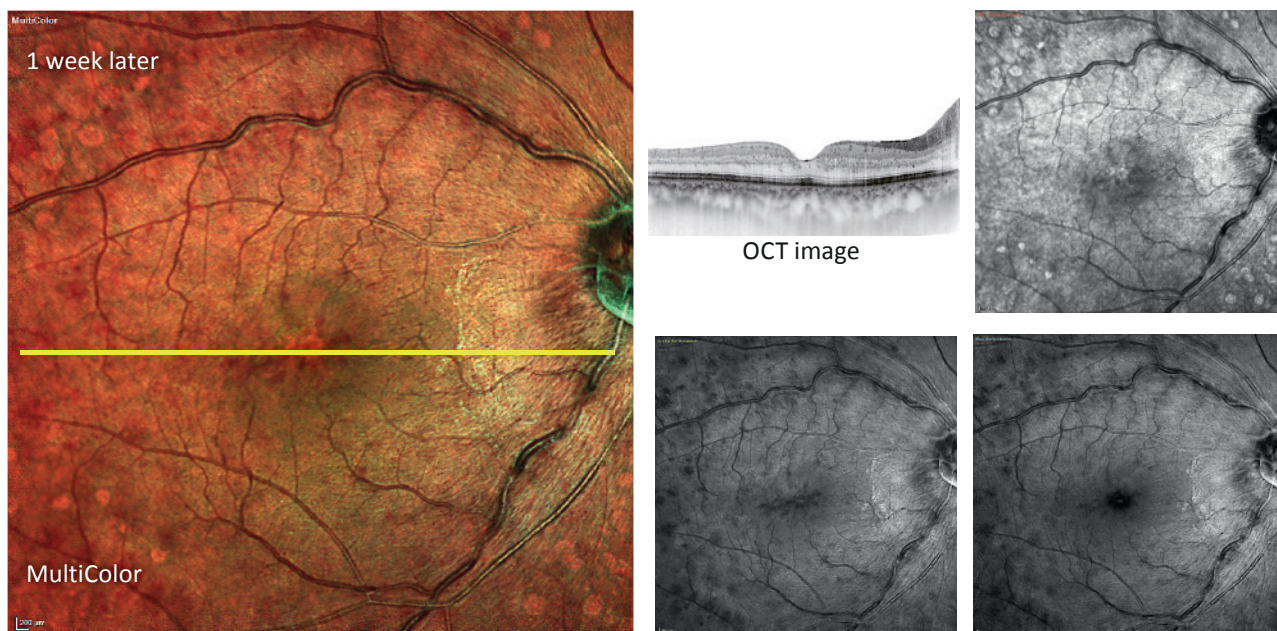
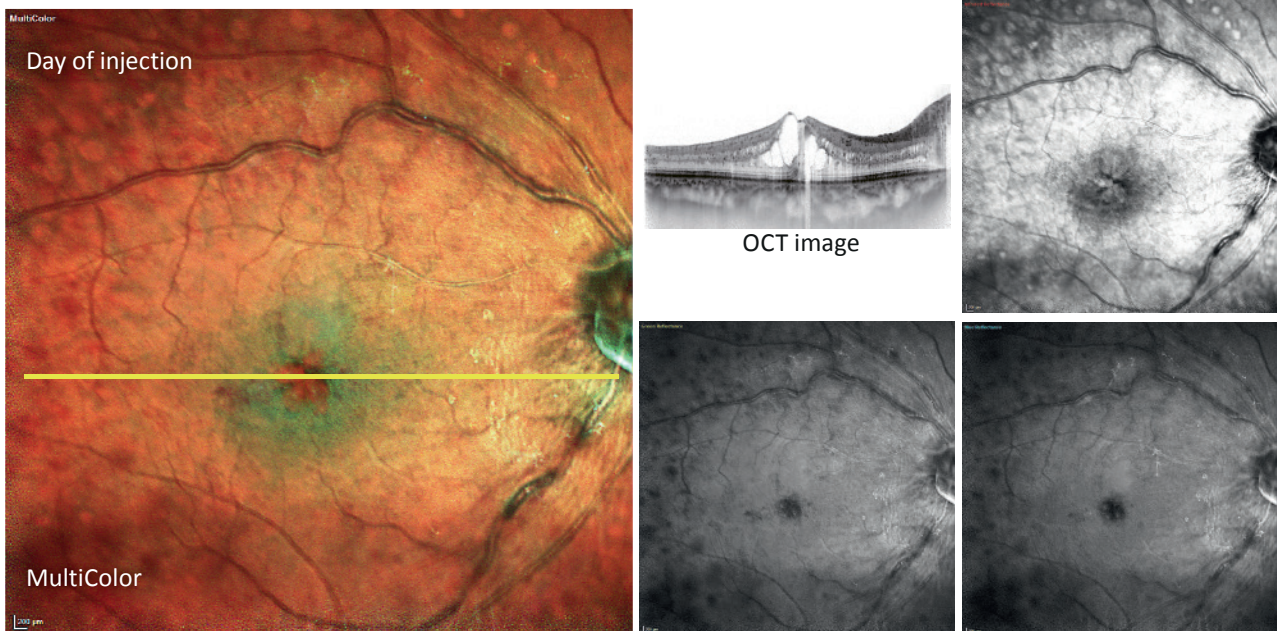
A case of retinal vascular occlusion (RVO) in the left eye of a 70-year old female. Corrected visual acuity of 0.6.

As in the case on the previous page, green enhancement shows the areas of retinal edema. The cyst morphology also appears clearly (blue arrow). The medium wavelength SLO image (outlined in red above) provides the greatest enhancement at the central arteriovenous level, and the abnormal vessels appear slightly white (yellow arrow). Vascular abnormalities such as tortuosity or dilation of capillaries are also easier to identify than in regular fundus images.

The lower three images show the progression following sub-Tenon's capsule triamcinolone acetonide injection (STTA) using MultiColor fundus images. One month after the STTA, the retinal edema (red arrows) and cyst had improved but the soft exudate remained (arrowhead). At two months, the edema had improved considerably, and the green coloring was considerably reduced. At three months, the coloring had almost returned to normal. The OCT image (not shown here) also showed that the retinal morphology was almost normal. As shown above, it is possible to gauge the condition of the retina and to identify the results of treatment using MultiColor fundus images.

Retinal Vascular Occlusion (RVO)

14. Central Retinal Vein Occlusion (CRVO)

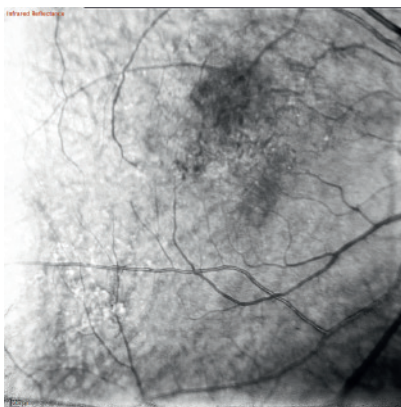
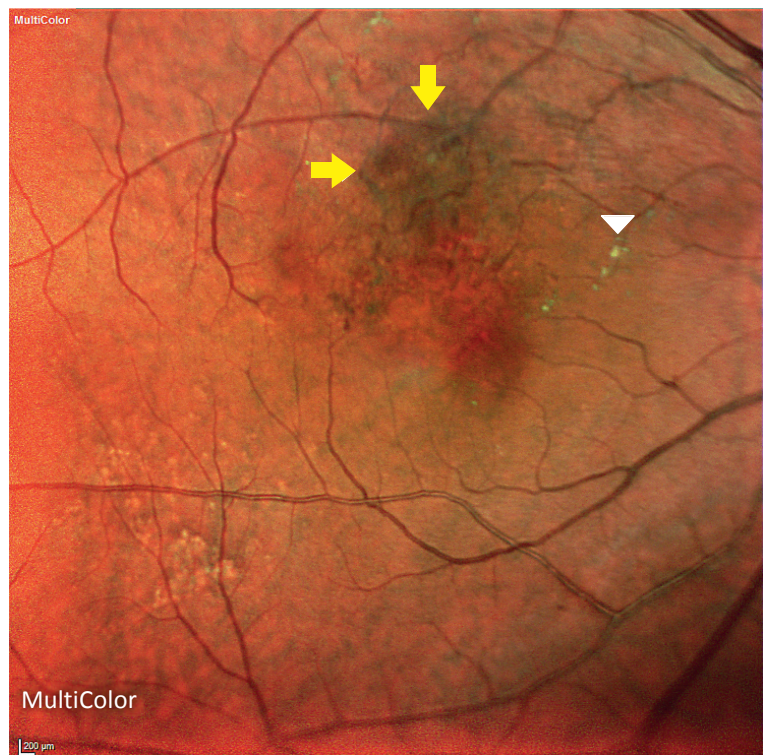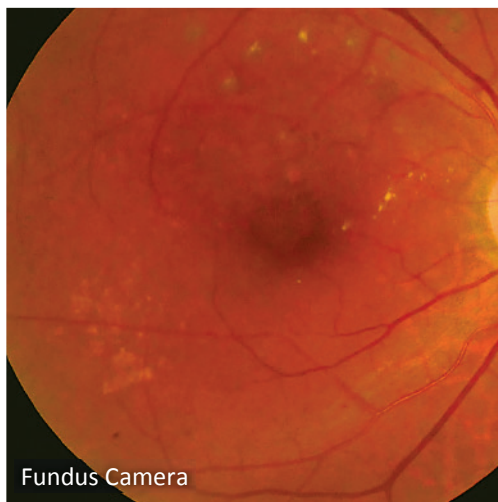


A case of central retinal vein occlusion (CRVO) in the left eye of a 65-year old female. Corrected visual acuity of 0.5.

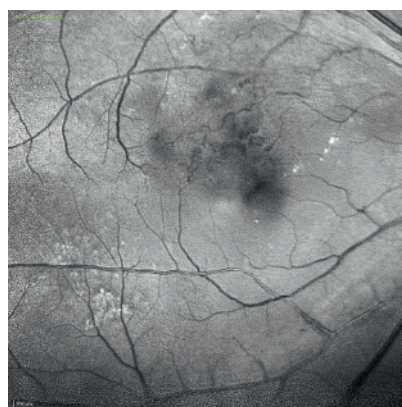Intravitreal bevacizumab (avastin) injection (IVB) was given for CRVO. Cyst and edema were observed in the macular region prior to treatment. The areas of the cyst and retinal edema appear in green in the MultiColor fundus image. 1 week after the IVB, it can be seen that treatment was successful and the retinal edema had been absorbed. Importantly, the findings in the MultiColor fundus images were consistent with the changes in OCT findings. As shown above, it is possible to use MultiColor fundus images to identify the effect of treatment for retinal vascular occlusion (RVO).

Retinal Vascular Occlusion (RVO)

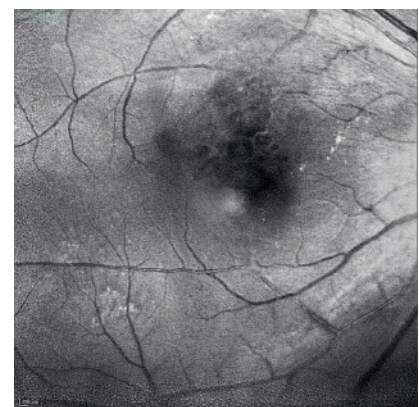15. Branch Retinal Vein Occlusion (BRVO)



Infrared: RPE level



Green: Retinal vessels



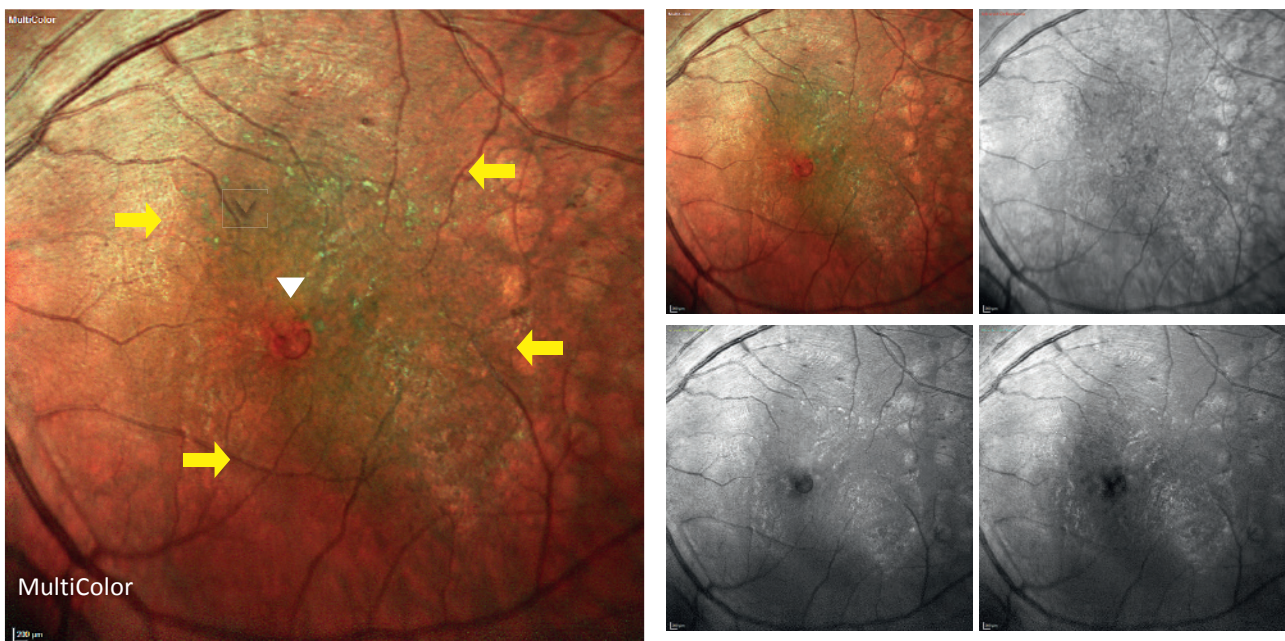
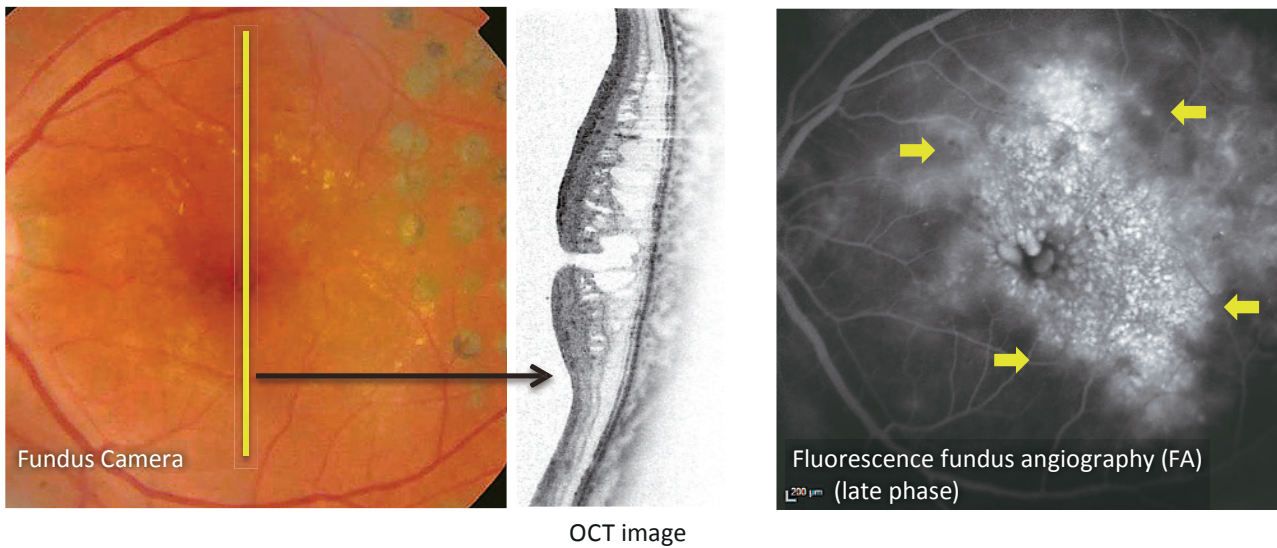
Blue: Retinal Surface

A case of branch retinal vein occlusion (BRVO) in the left eye of a 72-year old female. Corrected visual acuity of 0.3.

A case of branch retinal vein occlusion (BRVO) in which some time had passed after onset with few subjective symptoms. Regular fundus images were difficult to interpret due to the presence of cataracts. In a MultiColor fundus image, slight atrophy of the retinal pigment epithelium (RPE) was observed in the macular region, and hemorrhagic edema was observed in the upper region (yellow arrows). Hard exudate was observed at the edges of the lesion, clearly demarcated in greenish-white (arrowhead). The use of MultiColor fundus images makes it possible to observe the minor changes associated with BRVO, even in the presence of cataracts.

Diabetic Macular Edema (DME)

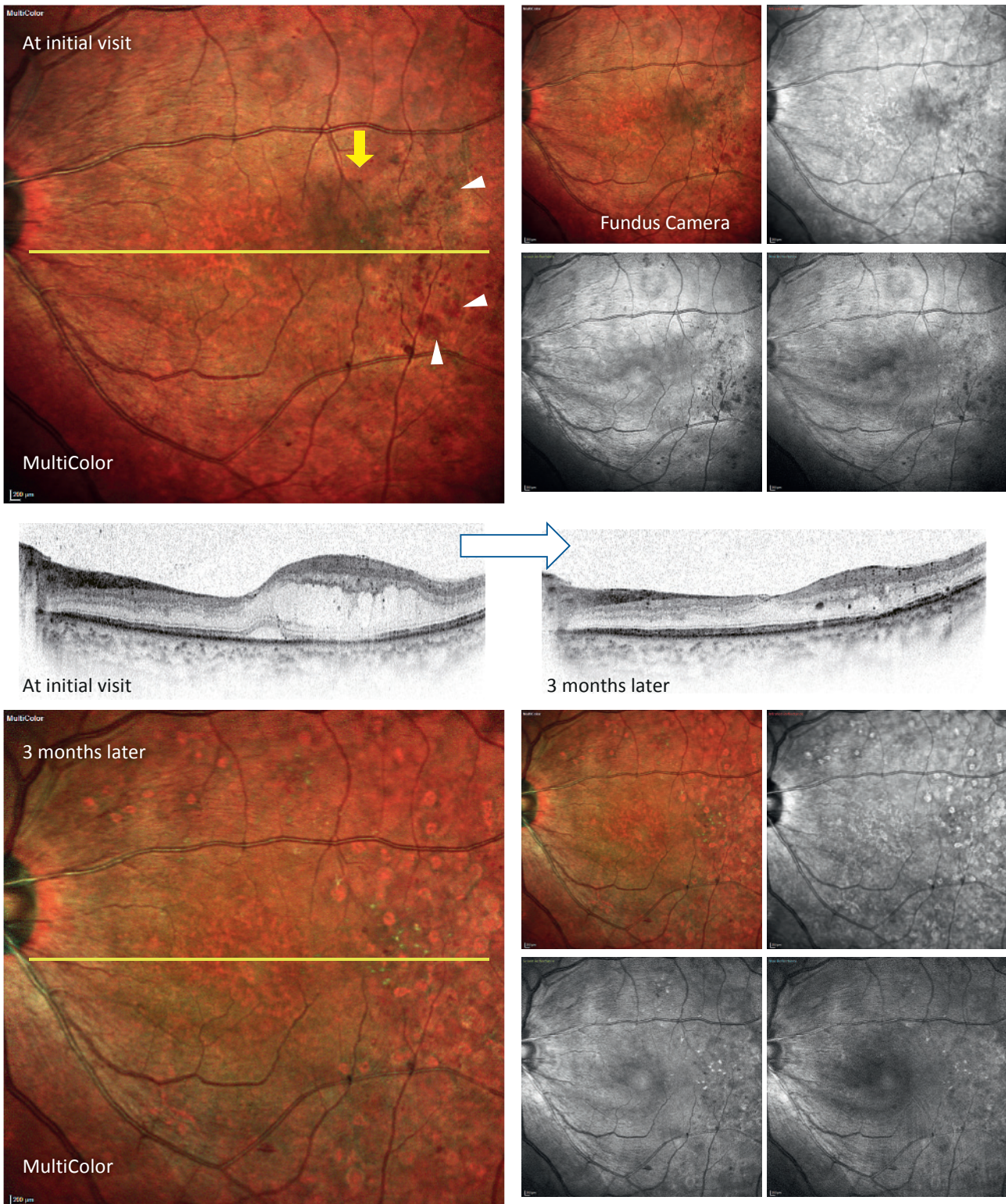
16. Diabetic Macular Edema (DME)



A case of diabetic macular edema (DME) in the left eye of a 63-year old male. Corrected visual acuity of 0.2. Hard exudate (clearly demarcated in greenish-white) and scarring from retinal photocoagulation were easily distinguishable in the MultiColor fundus image (although the coloring used differs from that used in regular fundus images). The lamellar hole in the macular region can be observed in OCT examination, but it is clearly evident in the MultiColor fundus image with slight red enhancement (arrowhead). The regions displayed in green in the MultiColor fundus image (arrows) are largely consistent with the leakage seen in late phase fluorescein angiography (FA). Leakage in the FA is difficult to confirm using a regular fundus image alone, so MultiColor fundus images can be useful in observing macular changes in diabetic retinopathy (DR), particularly in diabetic macular edema (DME).

Diabetic Macular Edema (DME)

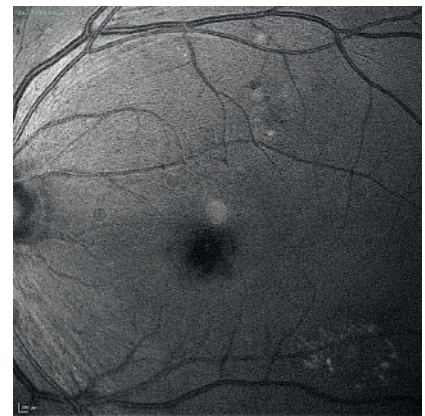
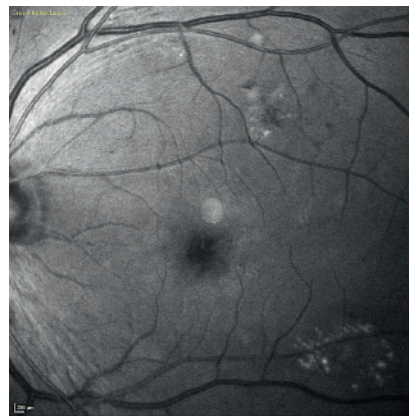
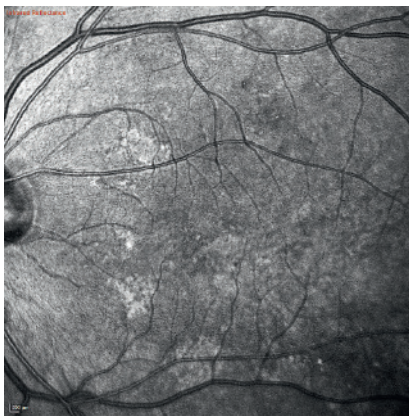
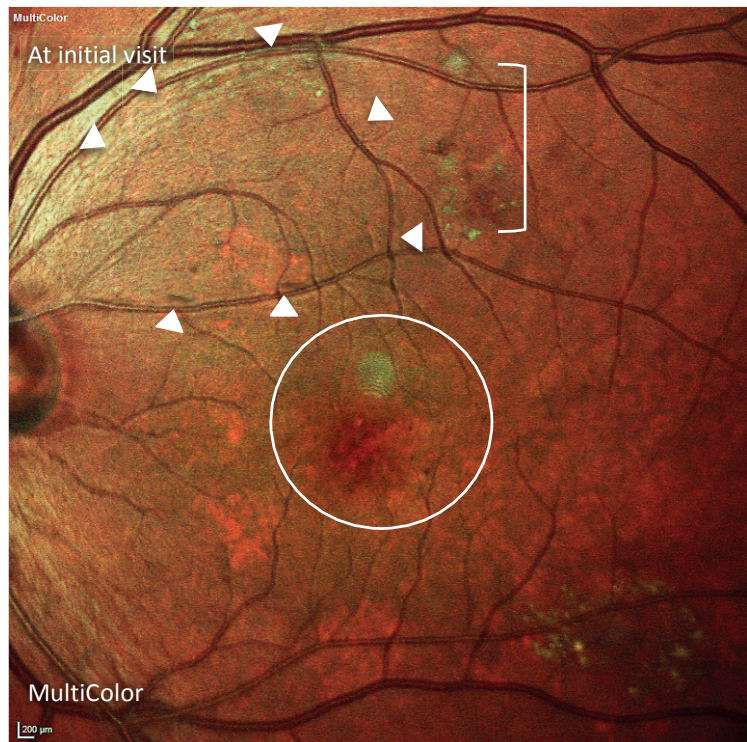
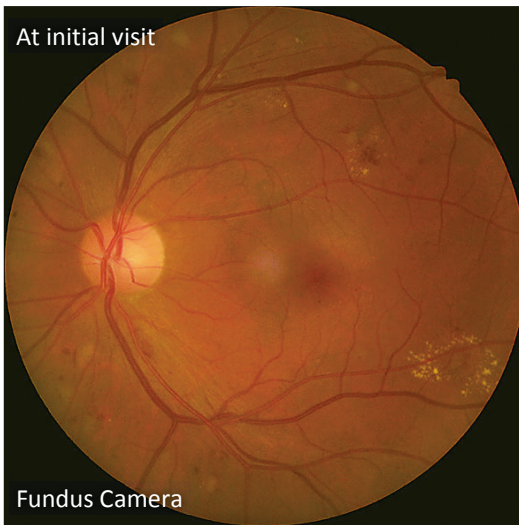
17. Diabetic Macular Edema (DME)



A case of diabetic macular edema (DME) in the left eye of a 65-year old female. In this case, MultiColor fundus images were useful for observing the course of treatment for DME. At the initial visit, edema (arrow) and hemorrhage (arrowheads) were evident in the temporal macular region. These findings were consistent with the OCT. Three months after focal PC of the region, the site of retinal photocoagulation and disappearance of the edema were clearly evident in the MultiColor fundus image. As shown above, MultiColor fundus images are extremely useful in determining the effectiveness of treatment for DME.

Diabetic Retinopathy (DR)

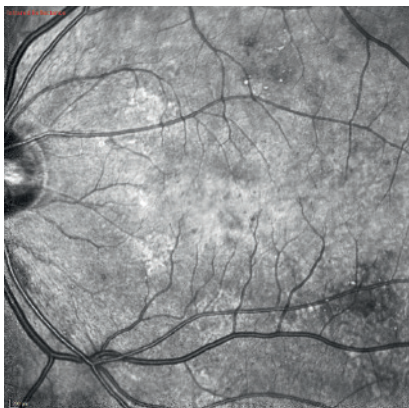
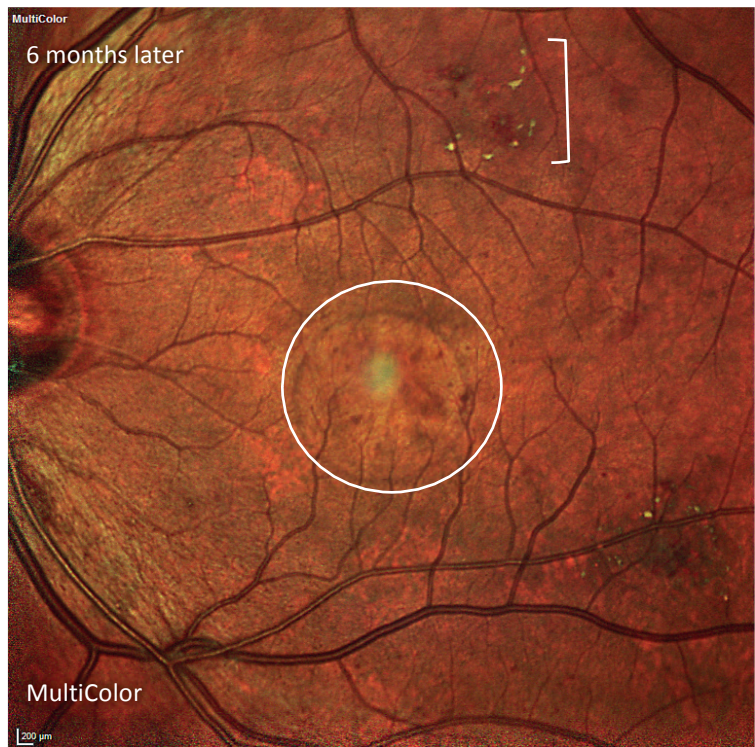
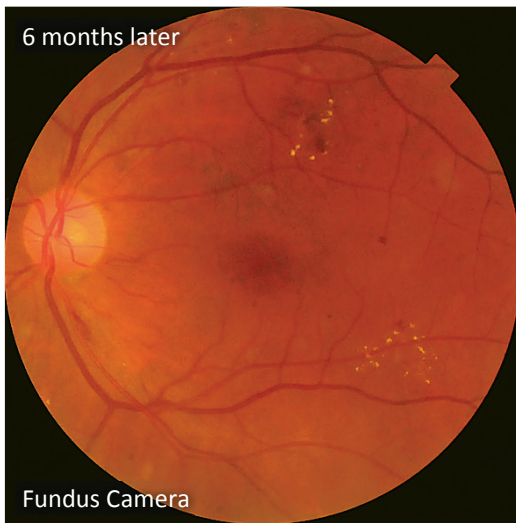
18. Diabetic Retinopathy (DR)



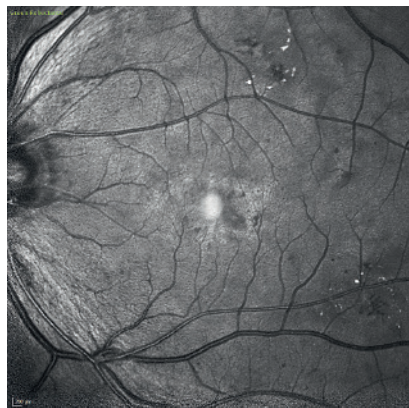A case of diabetic retinopathy (DR) in the left eye of a 67-year old male. Corrected visual acuity of 1.0.

In this case, MultiColor fundus images were useful for observing the course of the diabetes mellitus. From the regular fundus image, it could be concluded that there was little change over six months. The composite MultiColor fundus image, and medium wavelength SLO image in particular, show that the retinal microaneurysm had grown after six months (circle). The soft exudate seen in the arcade vessel at the initial visit had disappeared after six months, while hard exudate had increased (bracket). As shown above, it is considered highly possible that MultiColor fundus images can be used to observe the minor changes associated with DR.

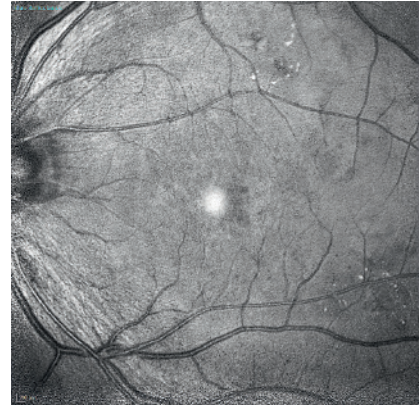
Diabetic Retinopathy (DR)



Infrared: RPE level



Green: Retinal vessels

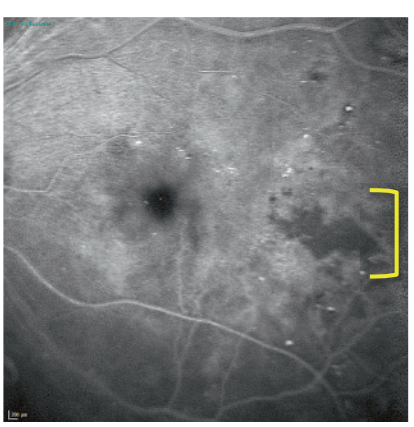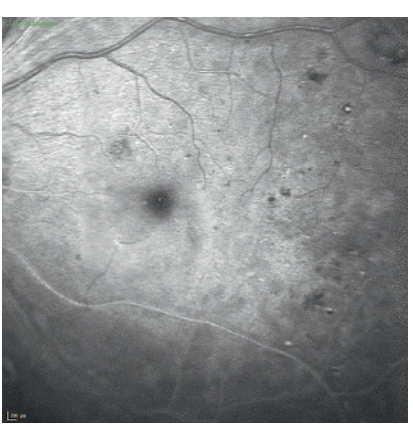
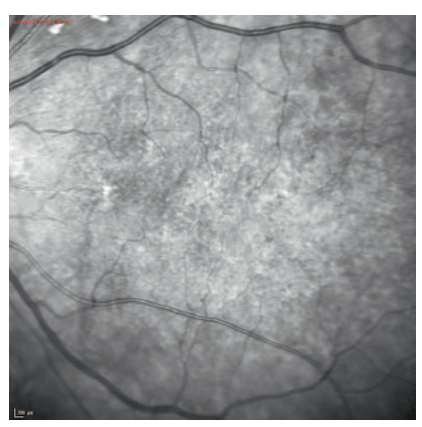
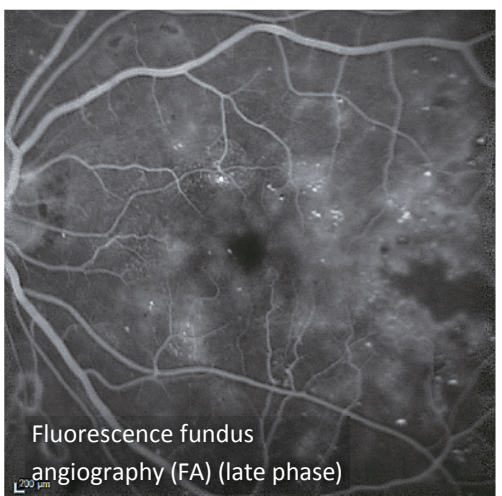

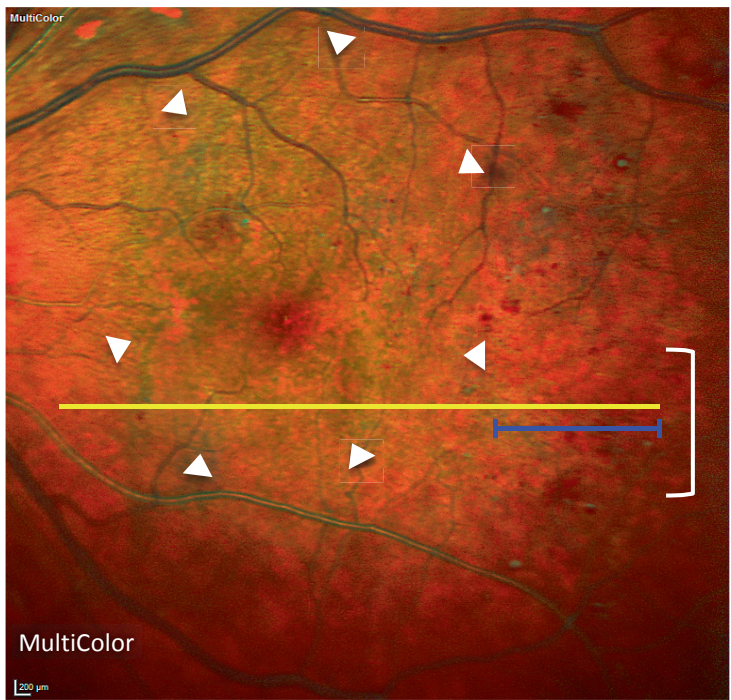
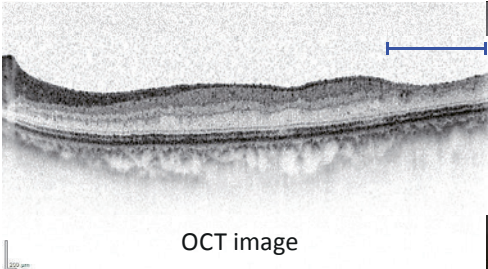
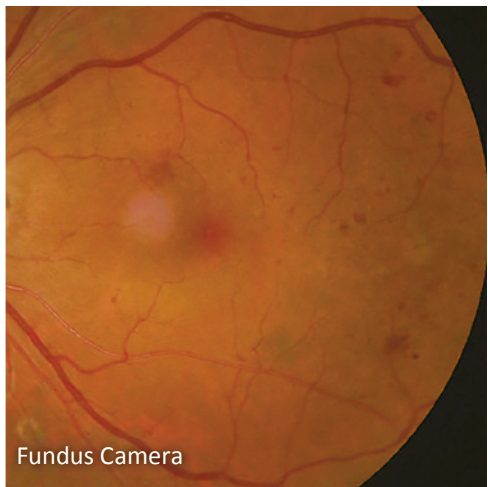


Blue: Retinal Surface

The retinal edema was not clearly evident in the OCT at the initial visit, but can be seen in green in the posterior upper medial region in the MultiColor image (within the arrowheads). This had returned to normal coloring after six months together with disappearance of the soft exudate. This may have been an artifact, but similar findings were observed in the patient on the following page. Although no edema is seen in OCT, it appears in green, which is consistent with the hyperfluorescent region in FA. I hope to continue studying MultiColor fundus images further in the future, since they seem to highlight minor changes.

Diabetic Retinopathy (DR)

19. Diabetic Retinopathy (DR)

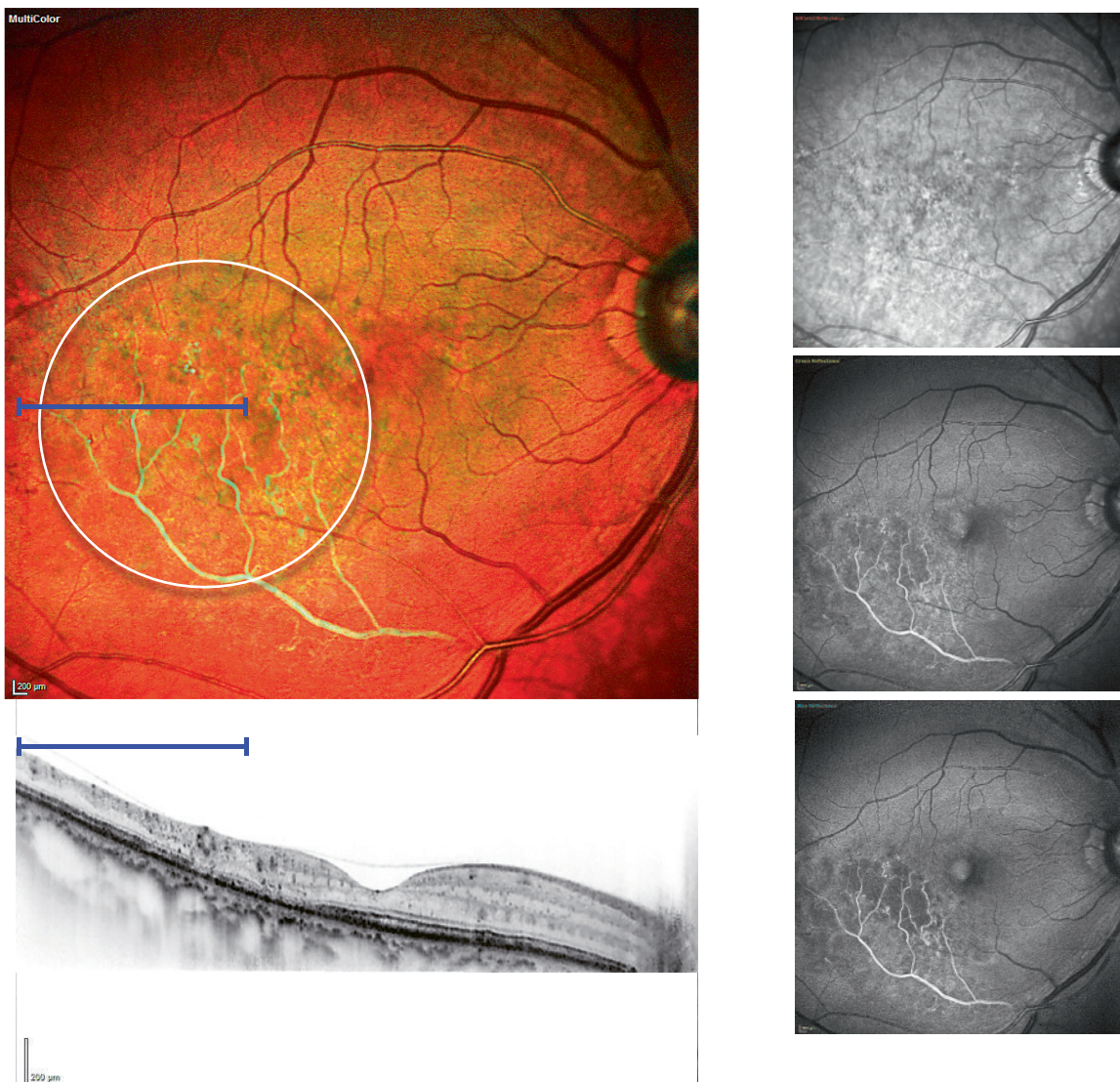


Retinal Vascular Occlusion (RVO)

(Previous page) **A case of diabetic retinopathy (DR) in the left eye of a 71-year old female. Corrected visual acuity of 0.8.** Regular fundus images may be affected by the presence of cataracts, and this may be interpreted simply as petechial hemorrhage. In the MultiColor fundus image, petechial hemorrhage appears as scattered red dots, and the region is enhanced in green which is consistent with the hyperfluorescent region in late phase FA (arrowheads). Most interestingly, and consistent with the morphology of the nonperfused regions present in the temporal macular region in FA, this appears reddish and faded in the MultiColor fundus image (white bracket). These changes are most clearly evident in the short wavelength SLO fundus image (yellow bracket). Thinning of the inner layer of the retina seen in OCT (blue bracket) can be picked up in the MultiColor Fundus Image.

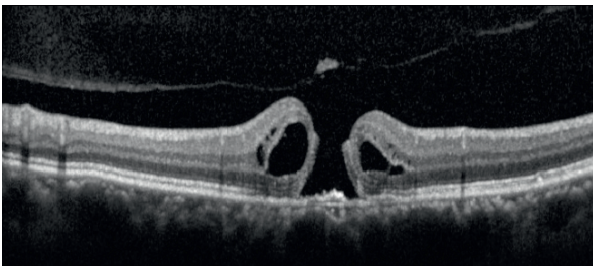
20. Retinal Vascular Occlusion (RVO)

(This page) **A case of retinal vascular occlusion (RVO) in the left eye of a 76-year old female.** As in the case of DR on the previous page, clearly demarcated regions can be observed in the MultiColor and short wavelength SLO fundus image (white circle). Thinning of the inner layer of the retina can be seen in OCT for the same regions (blue bracket). This patient was in generally poor condition, so it was not possible to perform FA. However, these two cases suggest that nonperfused regions may be clearly demarcated in MultiColor images, which may be of help in determining the suitability of photocoagulation or other treatments. These cases show the potential of MultiColor as a non-invasive test.

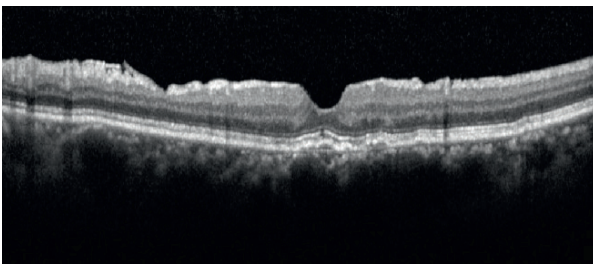


Macular Hole (MH)

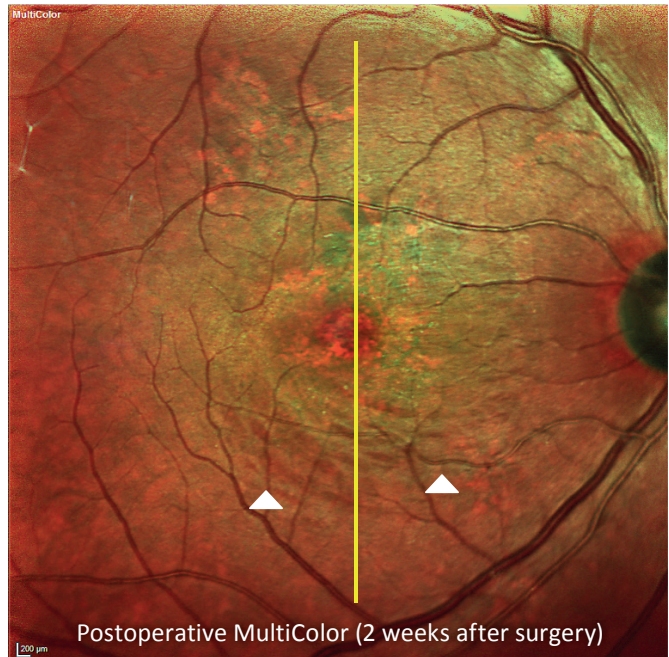
21. Macular Hole (MH)



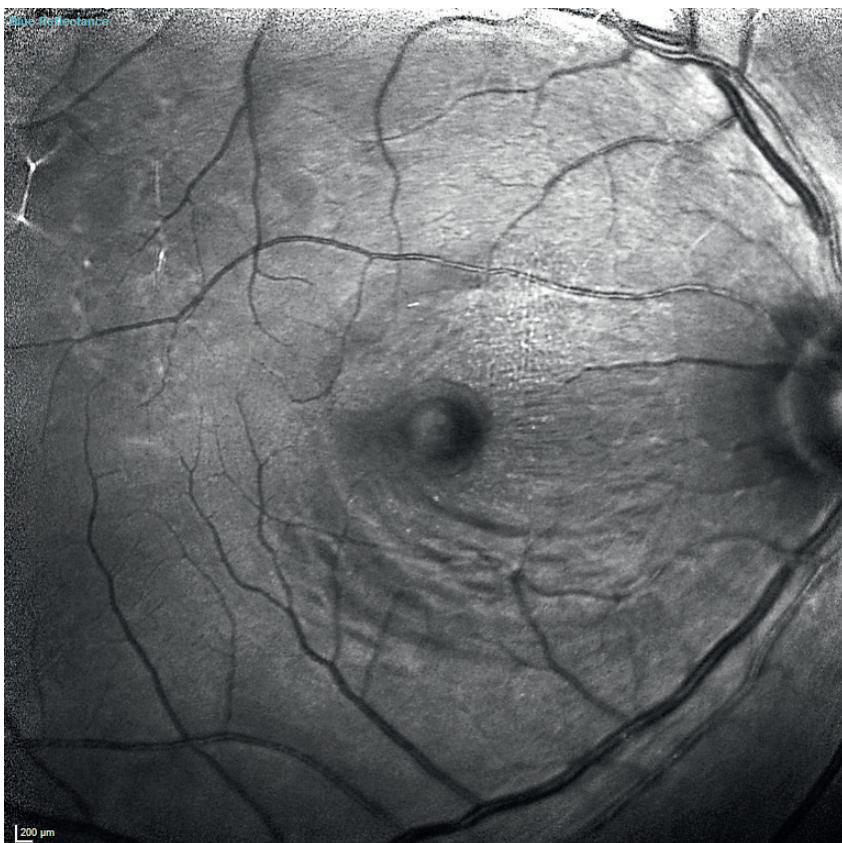
Preoperative OCT



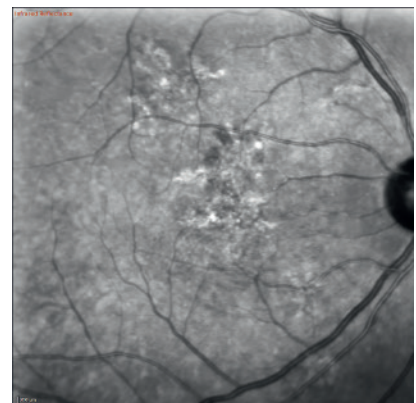
Postoperative OCT (2 weeks after surgery)



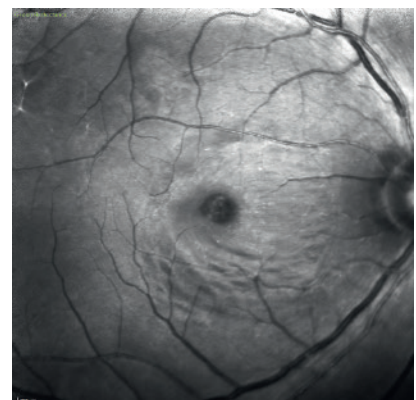
Postoperative MultiColor (2 weeks after surgery)



Blue: Retinal Surface



Infrared: RPE level

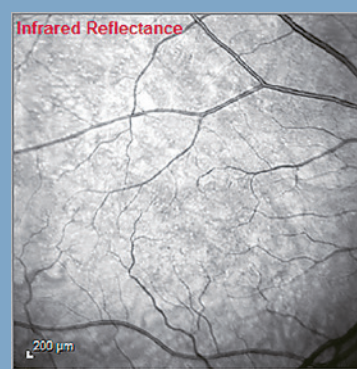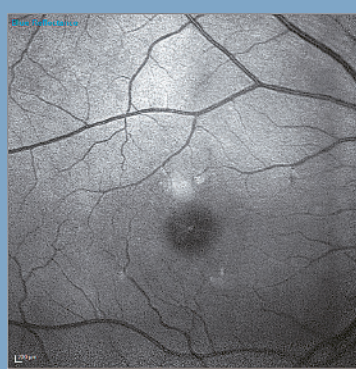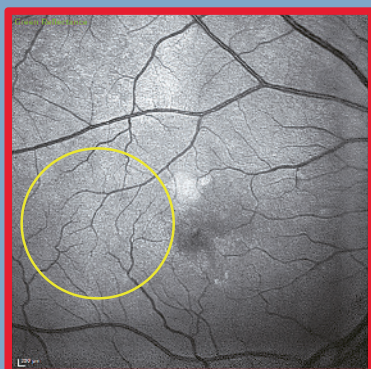
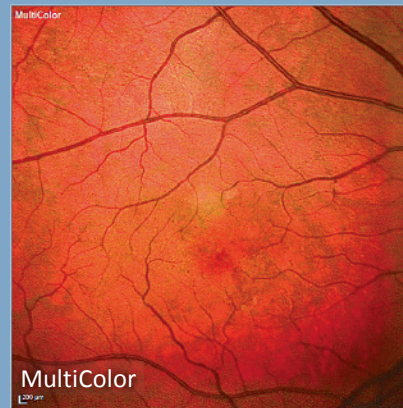


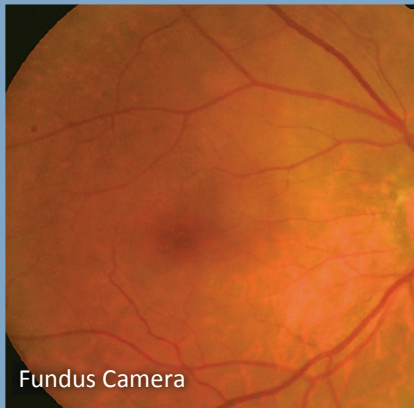Green: Retinal vessels

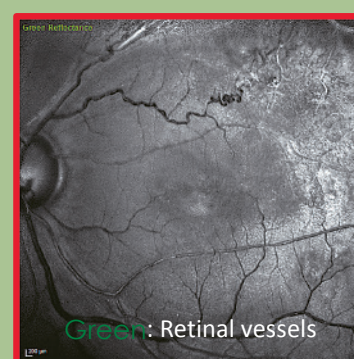
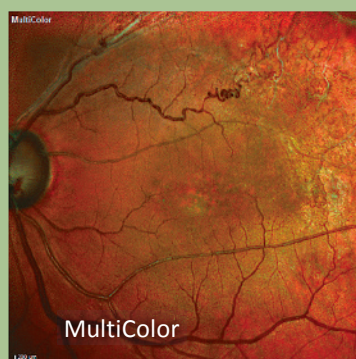
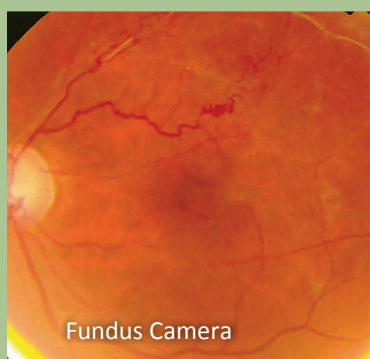
A case of macular hole (MH) in a 67-year old male.

The MH closed following vitrectomy. No clear tissue damage or edema were evident in OCT. In the MultiColor fundus image, however, there was green enhancement around the macular region and abnormal coloring in an arc shape along the retinal nerve fibers. This case suggests that MultiColor captures retinal changes that are not captured in regular fundus images or linear OCT scans. (This can be interpreted as changes to the retinal surface since the area is most pronounced in the blue wavelength SLO fundus image.)

MultiColor and Observation of the Retinal Vessels



This set of images shows a case of diabetes mellitus in a 56-year old female. The posterior petechial hemorrhage that would probably have been overlooked in the regular fundus image is clearly evident in the MultiColor fundus image. Changes to retinal vessels are best interpreted using green wavelength SLO fundus images. Apart from the posterior hemorrhage, enlarged vessels appear in the temporal macular region (within the circle).

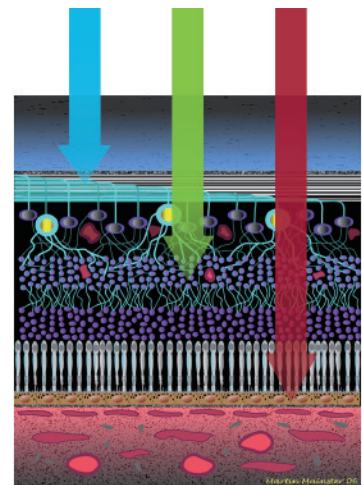


The bottom row shows a case of retinal vascular occlusion (RVO) in a 61-year old female. As with the previous case, vascular abnormalities are clearly evident in the green wavelength SLO fundus image. It is possible to assess minor vascular changes over time using MultiColor green wavelength SLO fundus images, which is of use in the treatment of conditions associated with abnormal changes in the retinal vessels.

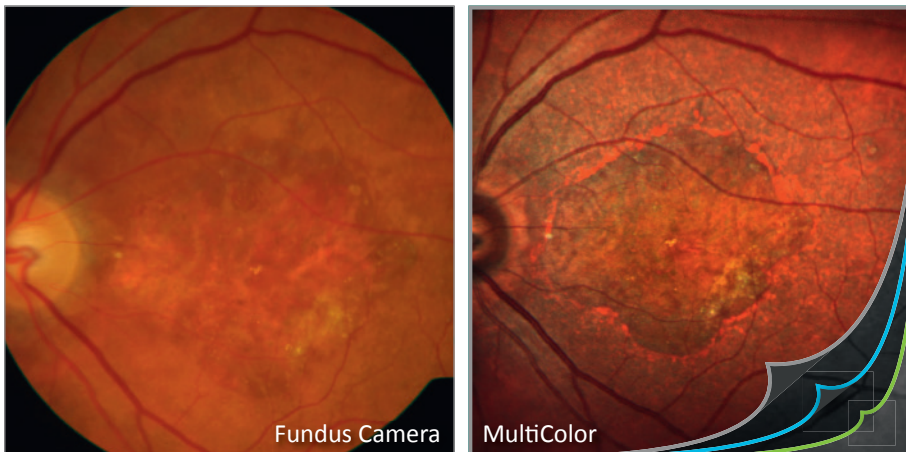Heidelberg Engineering - SPECTRALIS MultiColor

MultiColor™ scanning laser imaging combines spectral domain OCT with fundus images captured by lasers of different wavelengths, to bring a new dimension to the SPECTRALIS multi-modality imaging platform.

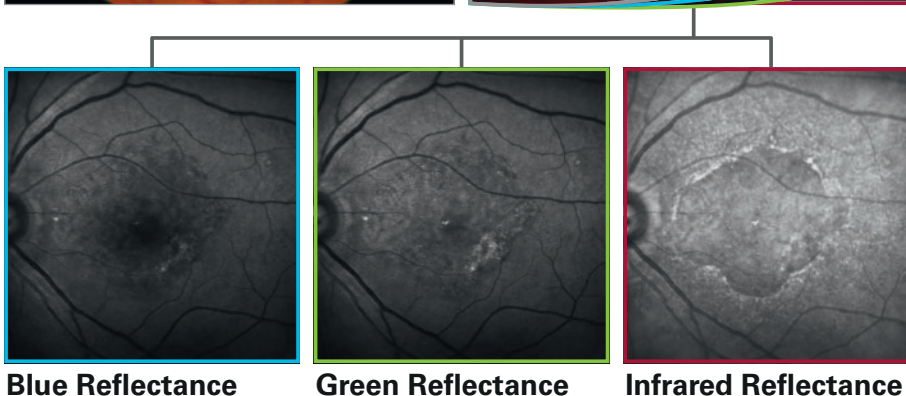
SPECTRALIS MultiColor makes it possible to capture high-contrast, detailed images even in patients with cataracts or nystagmus in whom imaging has previously proved difficult. SPECTRALIS core technologies of confocal scanning laser ophthalmoscopy, active eye tracking and noise reduction are employed to provide clear images down to the smallest detail.



The Versatility of MultiColor Imaging



The area of geographic atrophy is clearly demarcated in the MultiColor image. In addition, the peripheral reticular drusen are more easily identified.



The versatility to view images of the individual laser colors in addition to the MultiColor image can provide a deeper understanding of anatomic and pathologic detail.

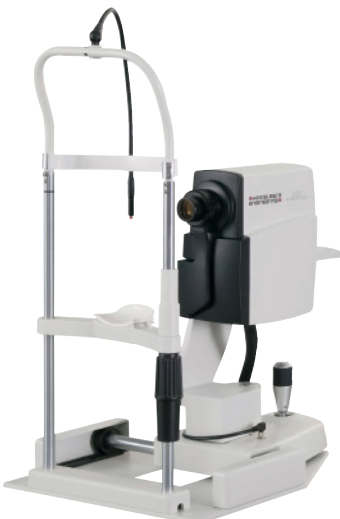Heidelberg Engineering - SPECTRALIS Models and Modalities.

	OCT SPECTRALIS	HRA+OCT SPECTRALIS	HRA SPECTRALIS
OCT	Retina	■	■
	Glaucoma	■	■
	Anterior Segment	option	option
	Nsite Analytics	option	option
	OCT2 Module (85,000 Hz)	option	option
Fundus	Infrared Reflectance	■	■
	BluePeak	option	■
	MultiColor	option	option
Widefield	Panning Camera	option	■
	Widefield Imaging (Fundus & OCT)	option	option
Angiography	Fluorescein Angiography		■
	ICG Angiography		option
	Ultra-Widefield Angiography		option

■ Standard feature. Some options can be added anytime; some are only available at initial equipment purchase.

SPECTRALIS OCT

The system has been made more compact, with the control panel and foot pedal used in the other SPECTRALIS models removed and eye tracker activation controlled using a joystick. MultiColor is optional.



SPECTRALIS HRA+OCT and HRA

The camera head may be moved which makes it easier to capture peripheral images. HRA may be upgraded to HRA+OCT. MultiColor is optional on all models.



**HEIDELBERG
ENGINEERING**

Headquarters

Heidelberg Engineering GmbH • Max-Jarecki-Str. 8 • 69115 Heidelberg • Germany
Tel. +49 6221 6463-0 • Fax +49 6221 646362

AUS

Heidelberg Engineering Pty Ltd • 404 Albert St. • East Melbourne 3002 • Victoria
Tel. +61 396 392 125 • Fax +61 396 392 127

UK

Heidelberg Engineering Ltd. • 55 Marlowes • Hemel Hempstead • Hertfordshire HP1 1LE
Tel. +44 1442 502 330 • Fax +44 1442 242 386

USA

Heidelberg Engineering, Inc. • 1808 Aston Avenue, Suite 130 • Carlsbad, CA 92008
Tel. +1 760-536-7000 • Fax +1 760-536-7100

www.HeidelbergEngineering.com