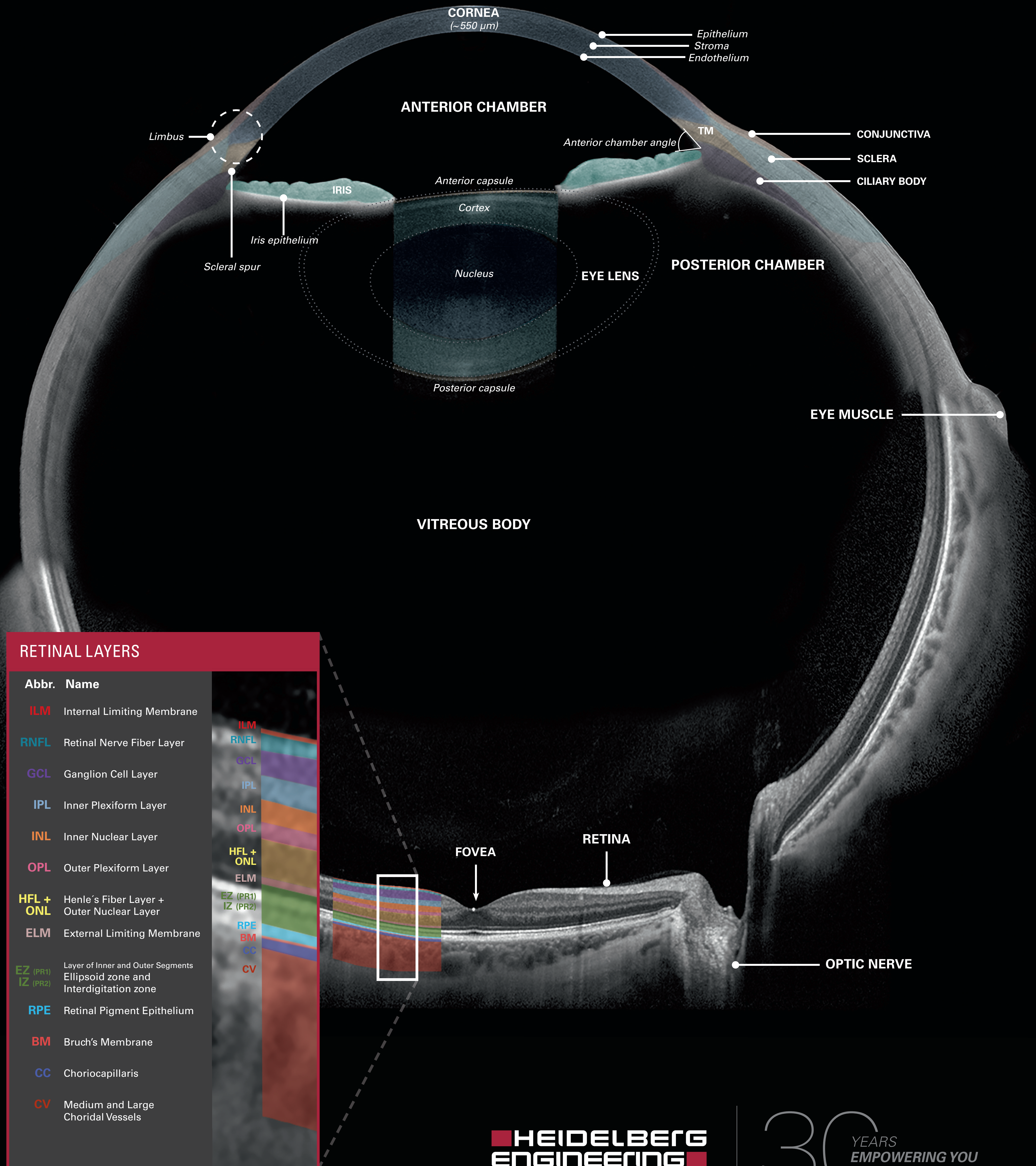


The Anatomy of the Human Eye:

Structural details seen in OCT images



RETINAL LAYERS

| Abbr. | Name |
|----------------------|--|
| ILM | Internal Limiting Membrane |
| RNFL | Retinal Nerve Fiber Layer |
| GCL | Ganglion Cell Layer |
| IPL | Inner Plexiform Layer |
| INL | Inner Nuclear Layer |
| OPL | Outer Plexiform Layer |
| HFL + ONL | Henle's Fiber Layer + Outer Nuclear Layer |
| ELM | External Limiting Membrane |
| EZ (PR1) IZ (PR2) | Layer of Inner and Outer Segments Ellipsoid zone and Interdigitation zone |
| RPE | Retinal Pigment Epithelium |
| BM | Bruch's Membrane |
| CC | Choriocapillaris |
| CV | Medium and Large Choroidal Vessels |

